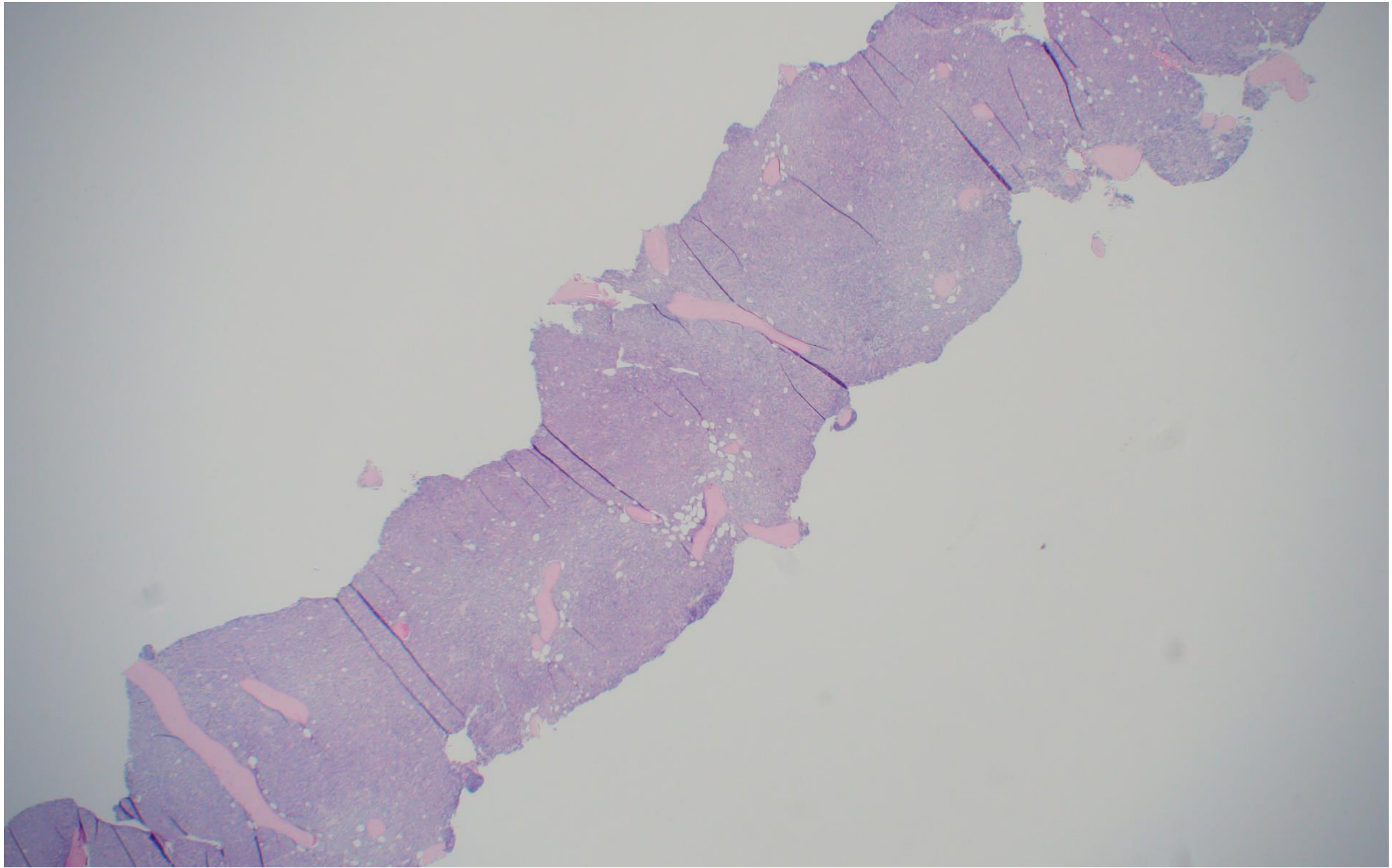
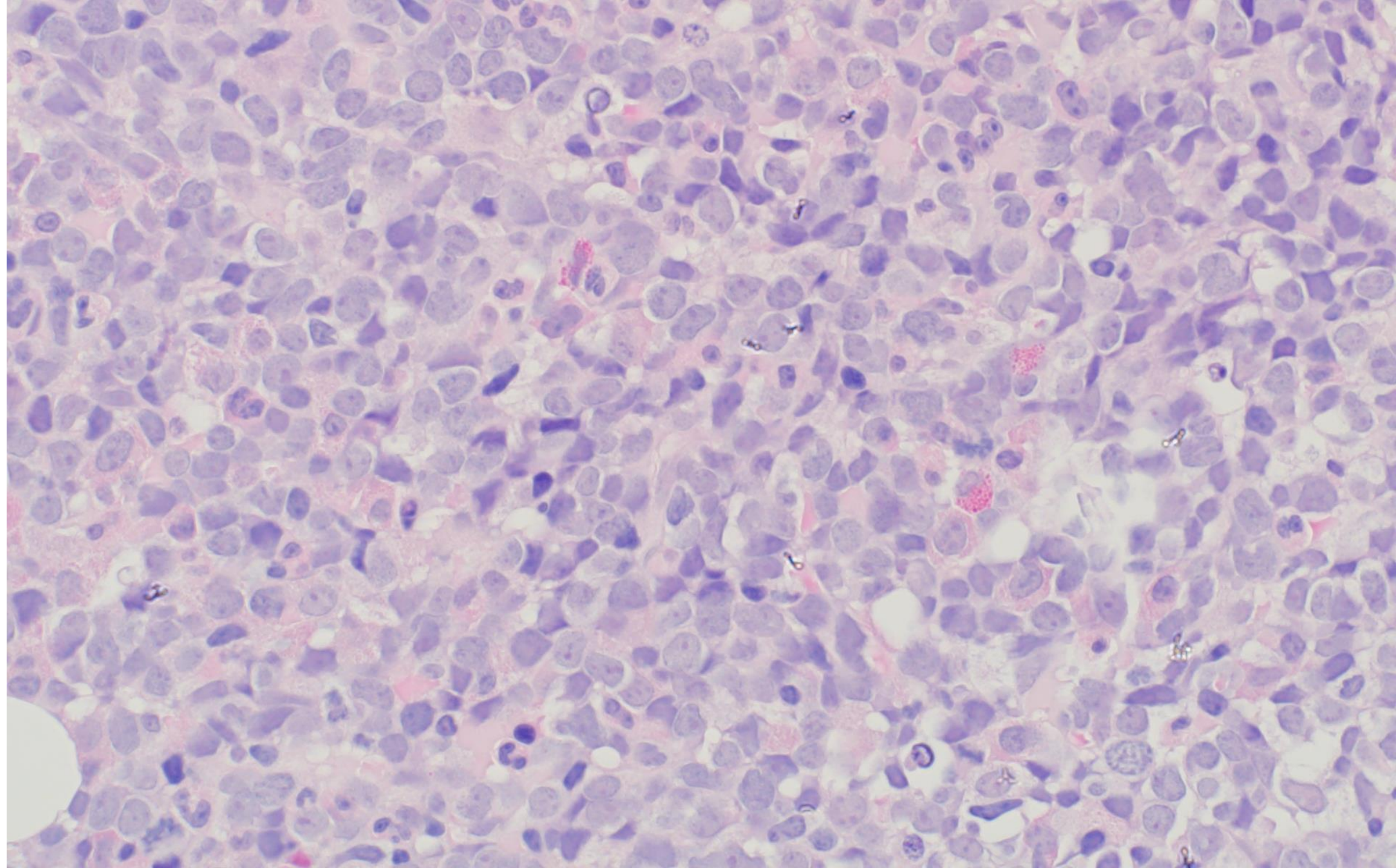
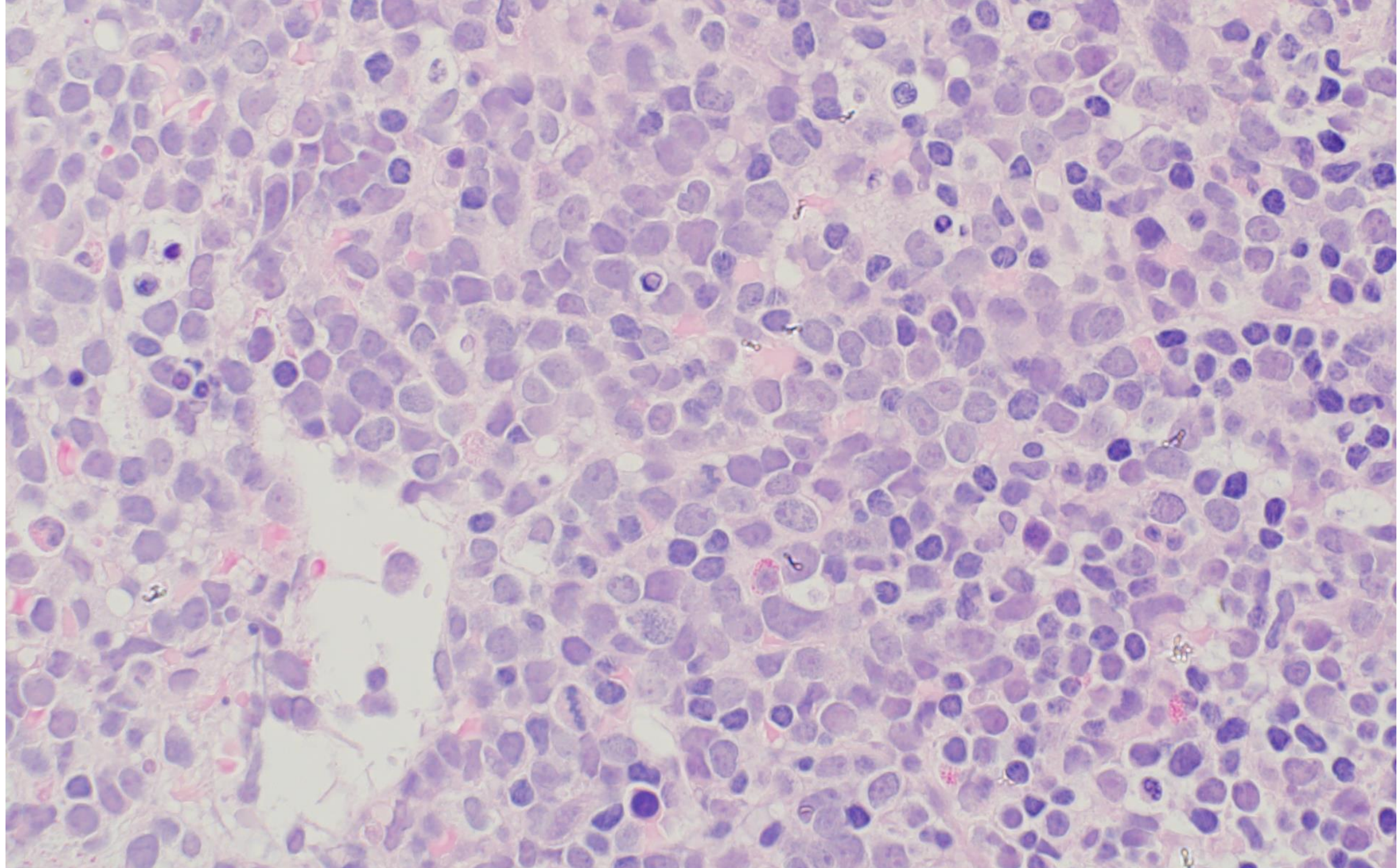


AA Case 3

- 55-year old male
- Bone marrow trephine
- New leukaemia or lymphoma
- Agranular blasts in blood film









Ki 67