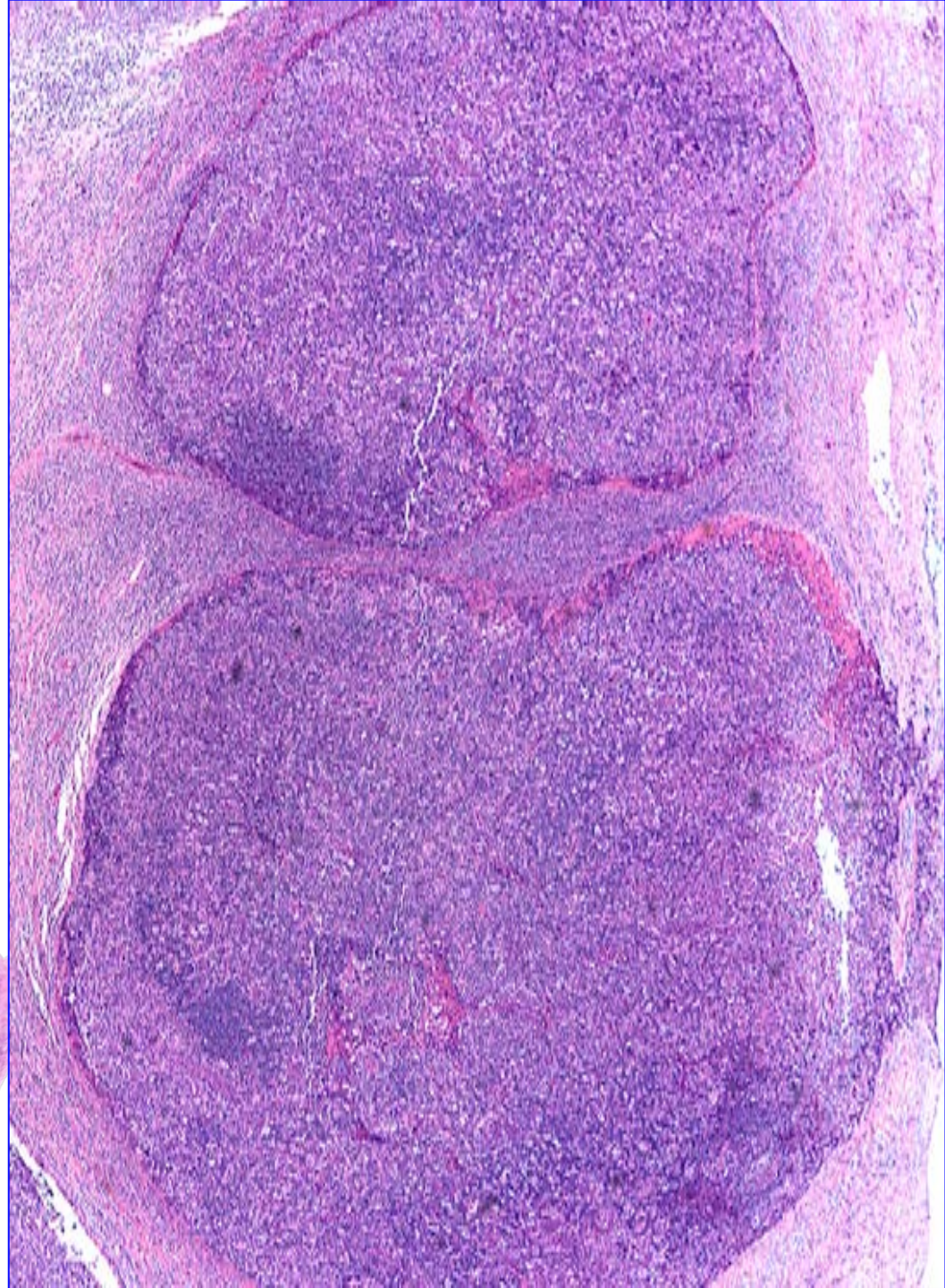
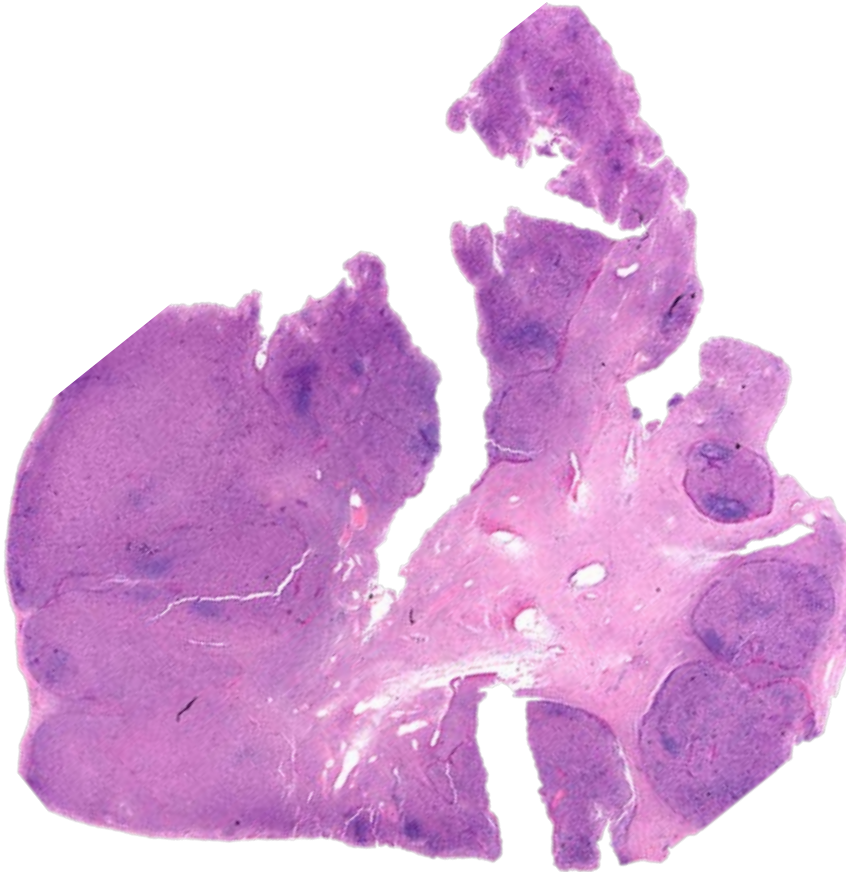
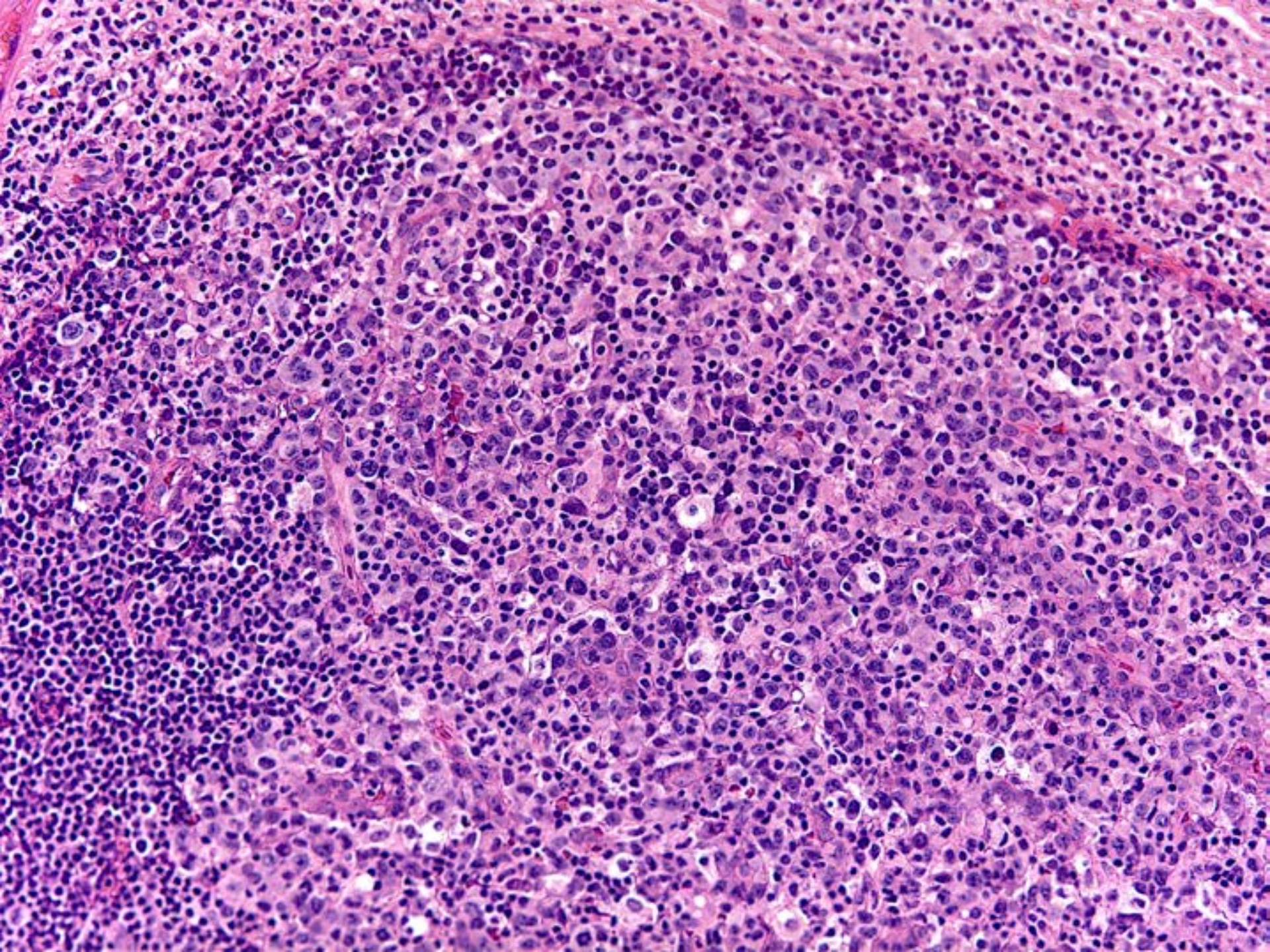
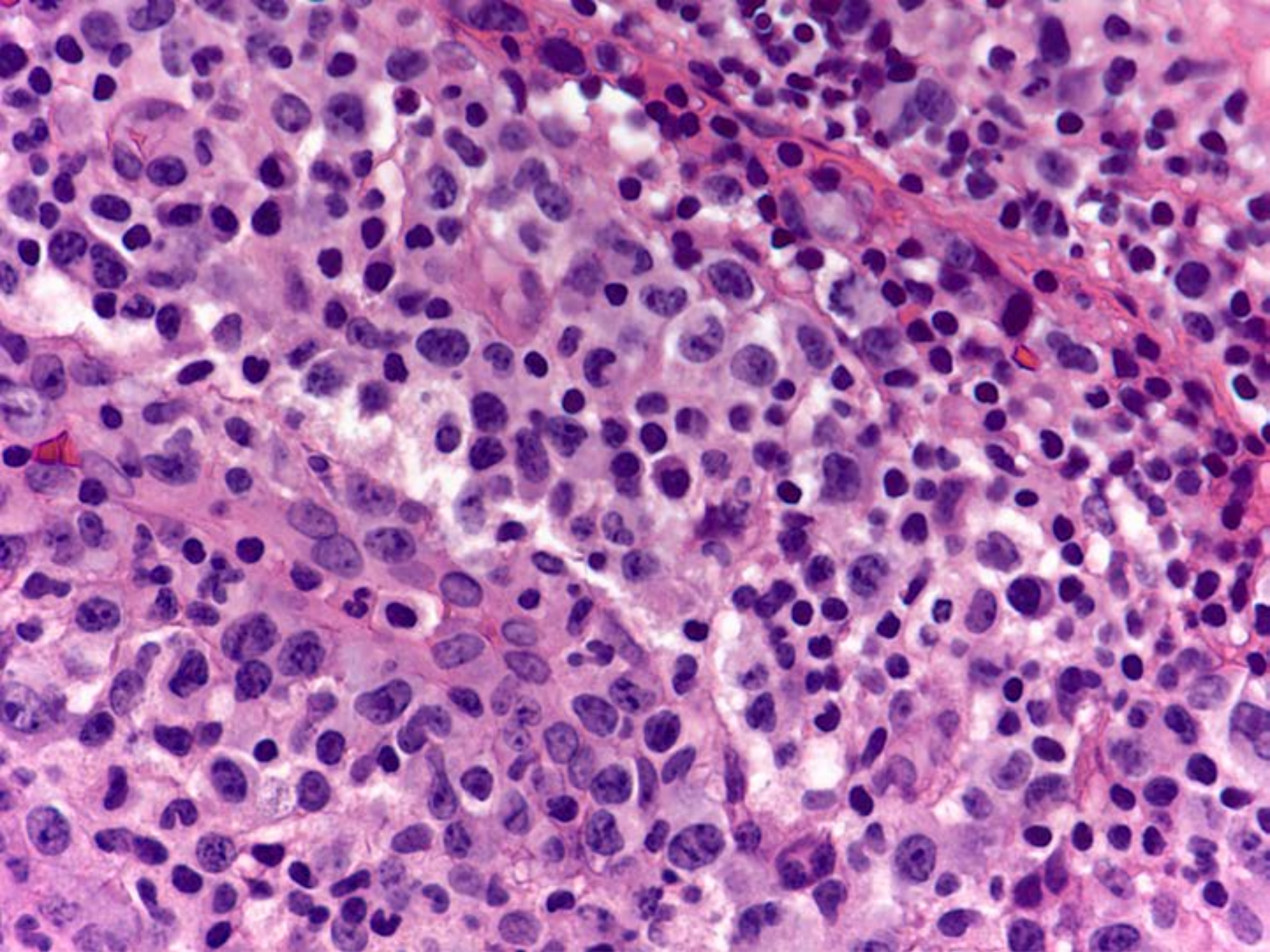


YN Case 6

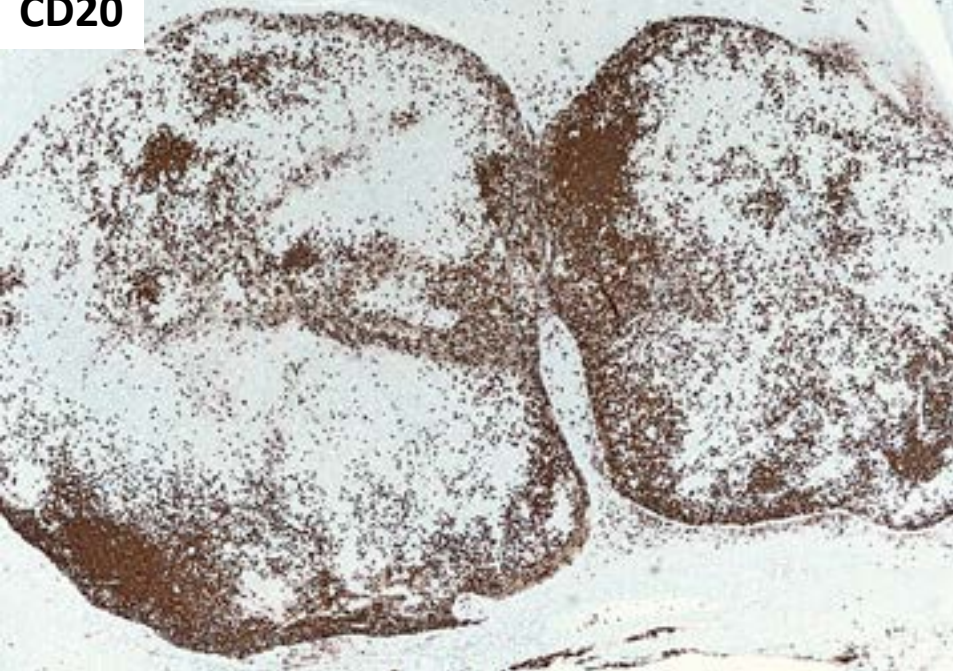- 17-year old boy with cervical and retroperitoneal lymphadenopathy
- Right cervical lymph node excision was performed



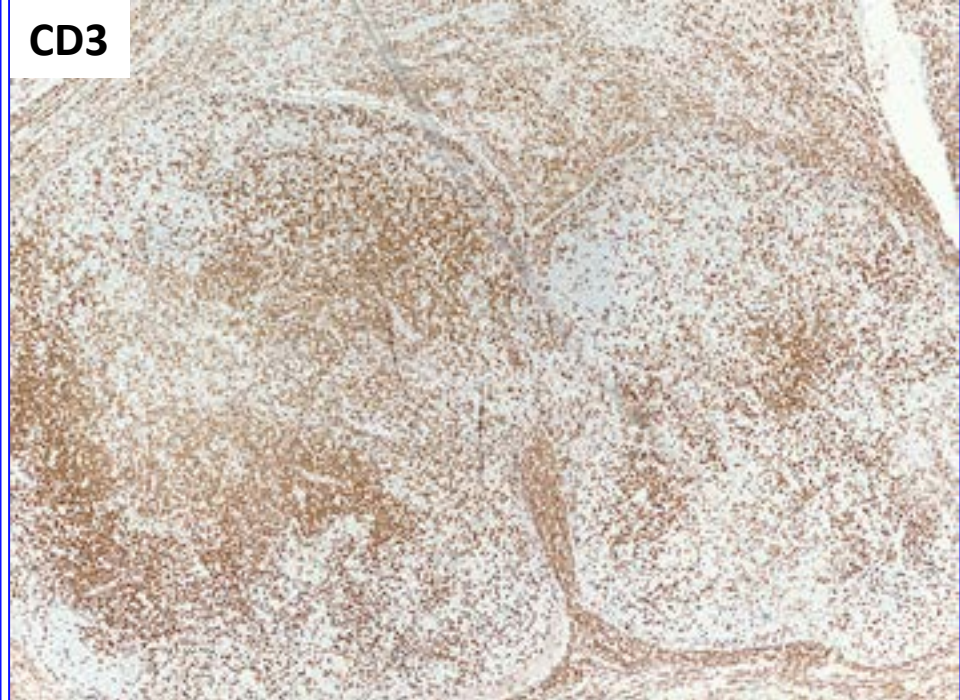




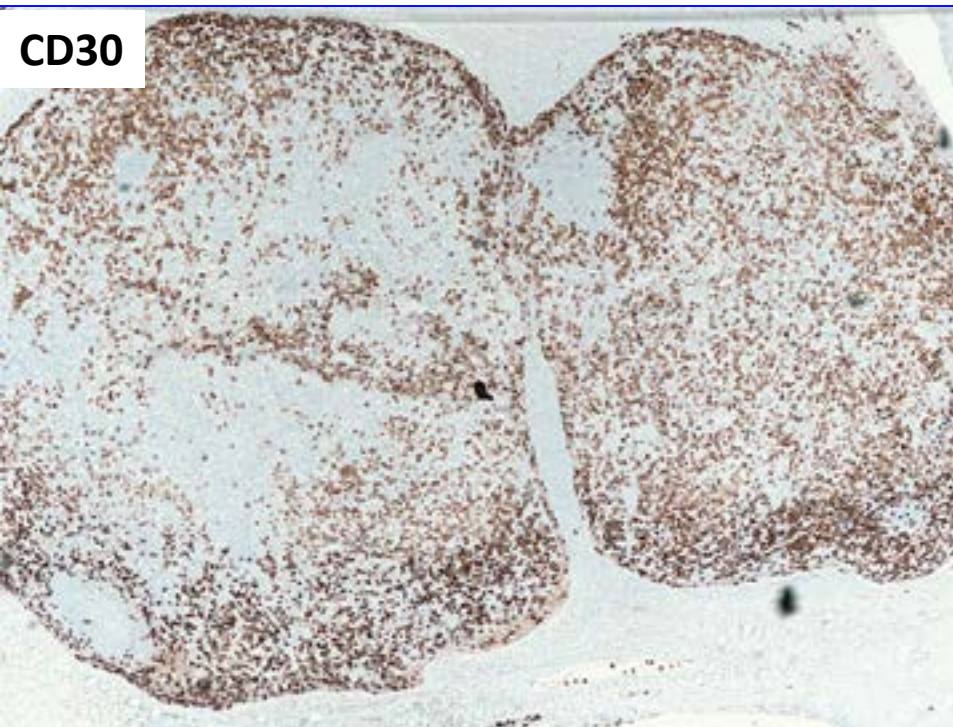
CD20



CD3



CD30



CD5

