

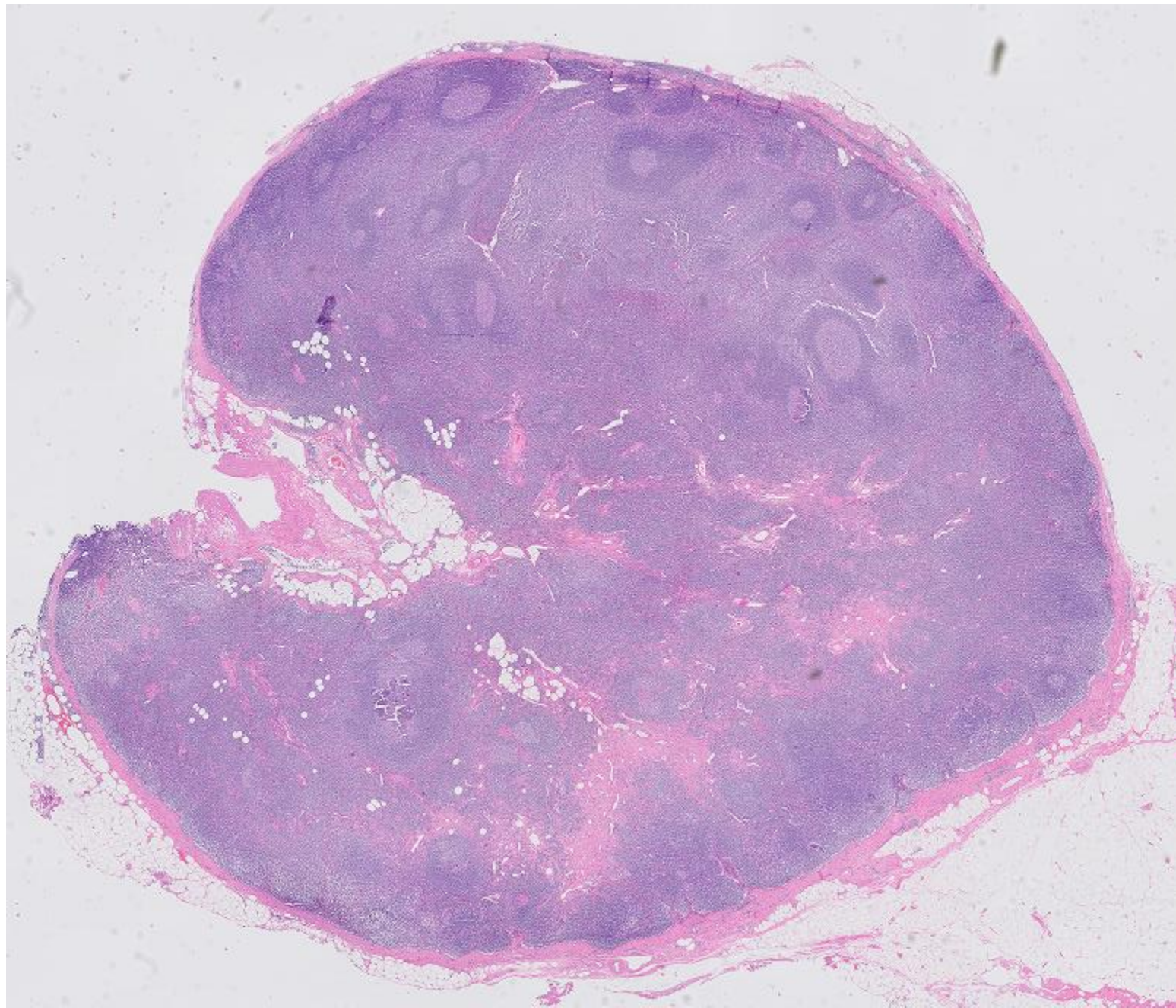
CPSL and EAHP Lymphoma Tutorial

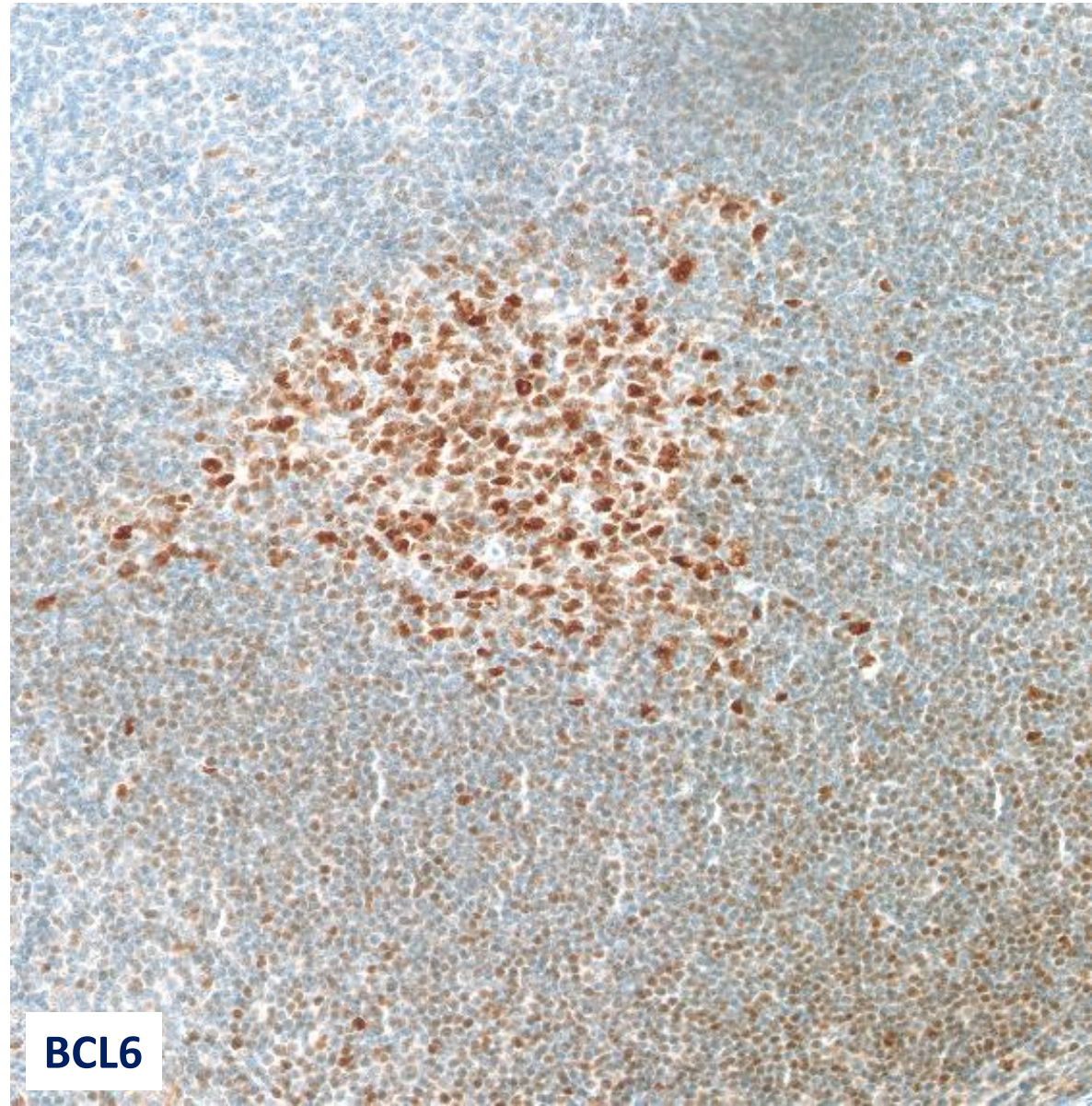
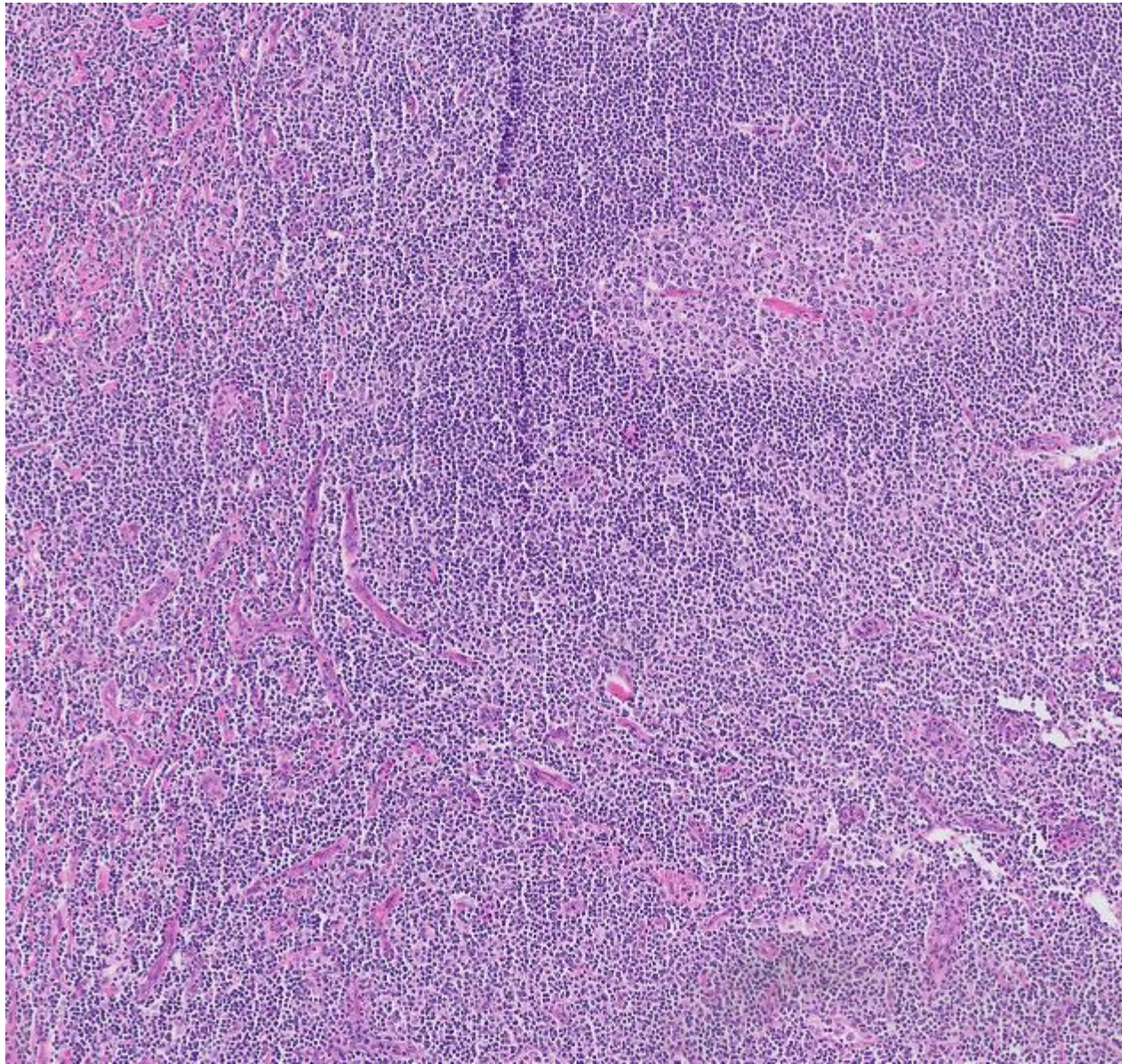
session: small B-cell lymphomas

Case: TVU19-69

Clinical information: A 57 year old man presented with abdominal lymphadenopathy with enlarged left inguinal, para-iliacal and para-aortal lymph nodes. No further lymphadenopathy was noted, no hepatosplenomegaly. Medical history was unremarkable

A left inguinal lymph node was submitted





BCL6