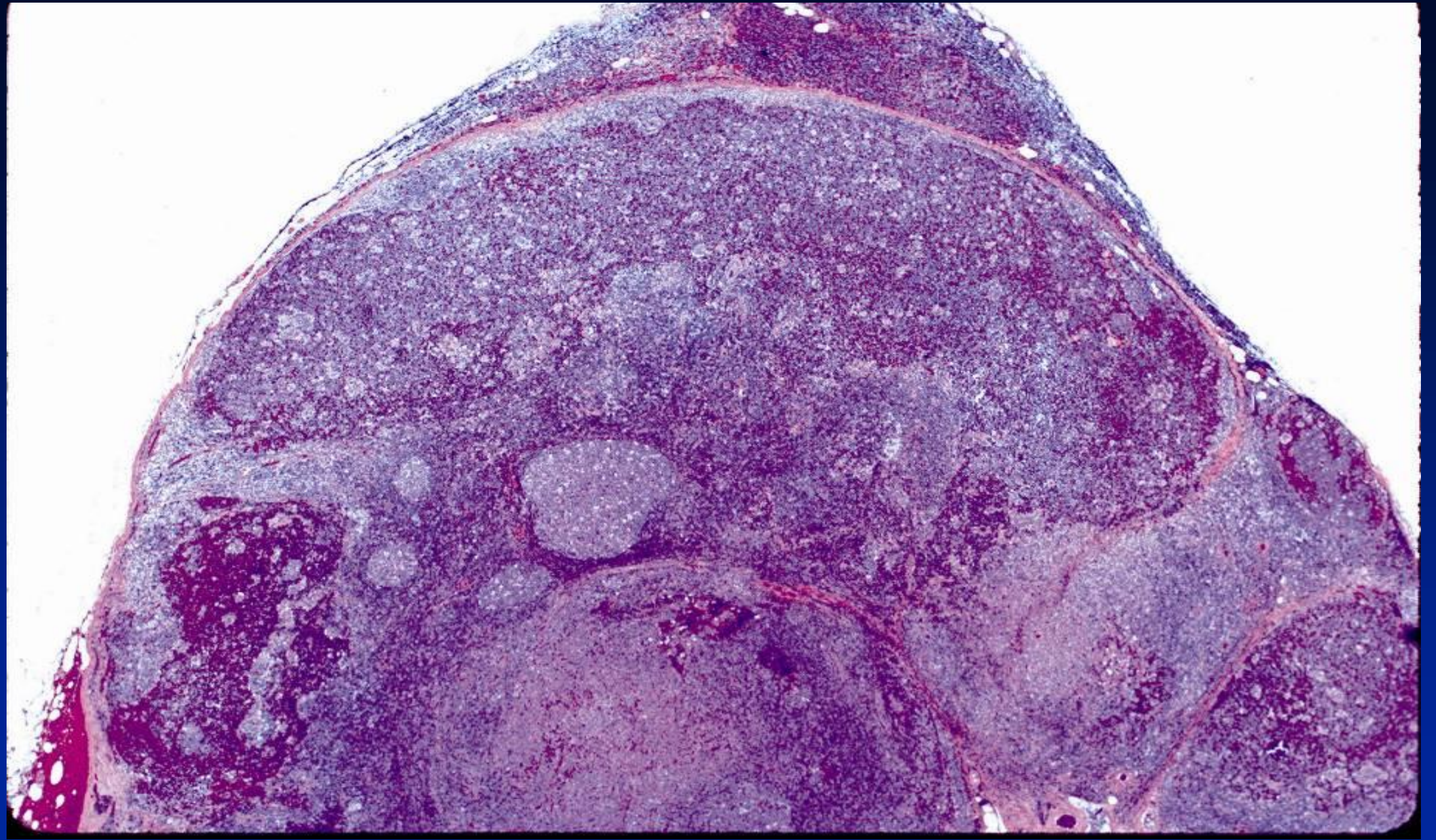


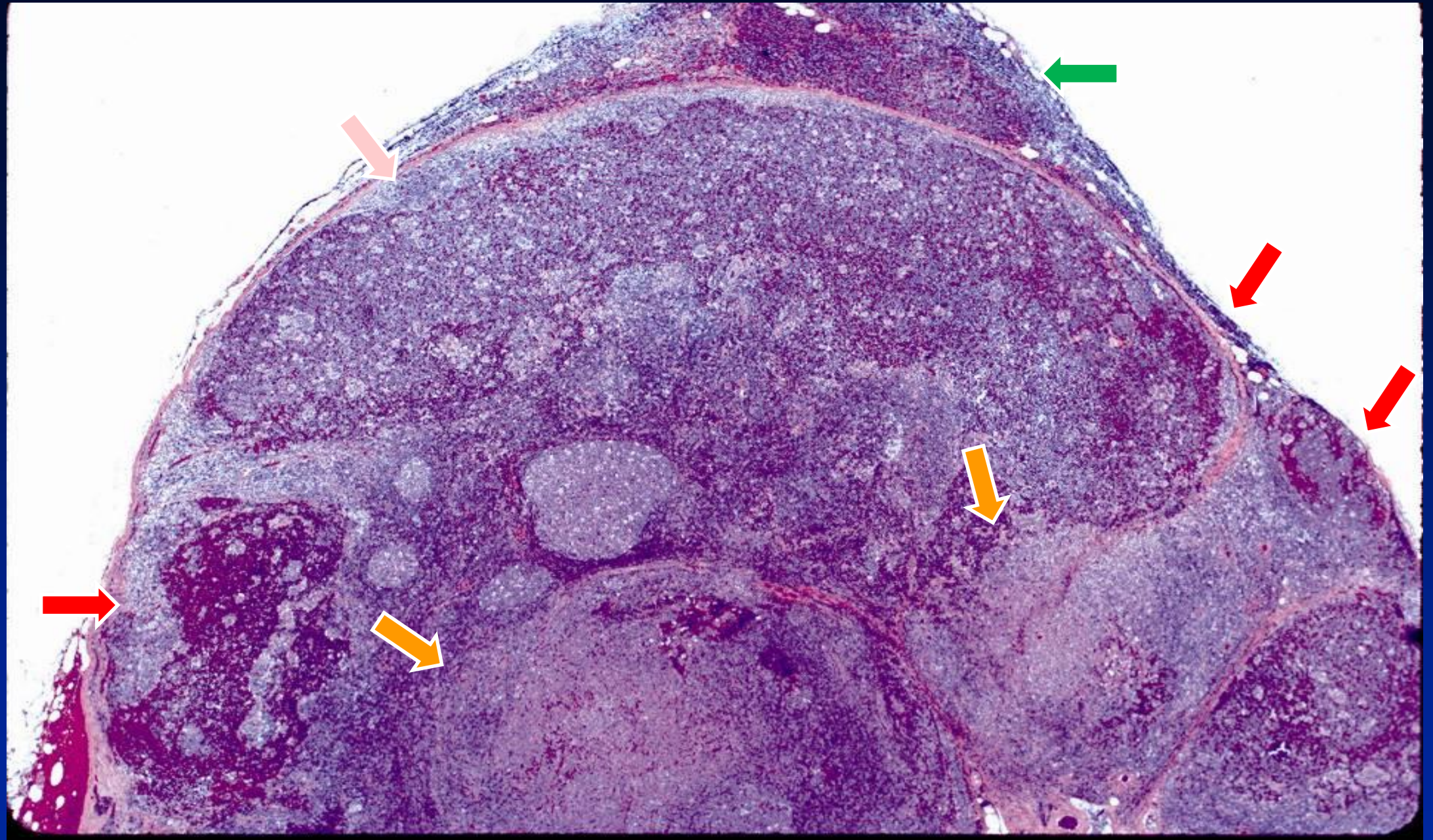
CASE: M

Biopsy Site: Male

Sex: Male

Photos: 3





Dilated subcapsular sinus

**Pericapsular:
blood, small cells**

**Follicular
lysis**

MBC

