GESTATIONAL TROPHOBLASTIC DISEASE AND RELATED LESIONS

- 35 yrs old patient with a history of molar pregnancy presented with vaginal bleeding. Curettage was perfomed and meterial sent for histology.

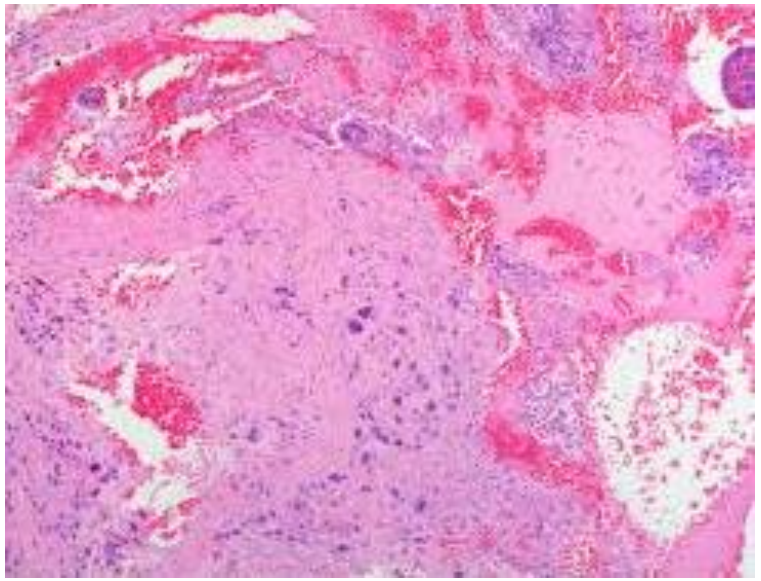

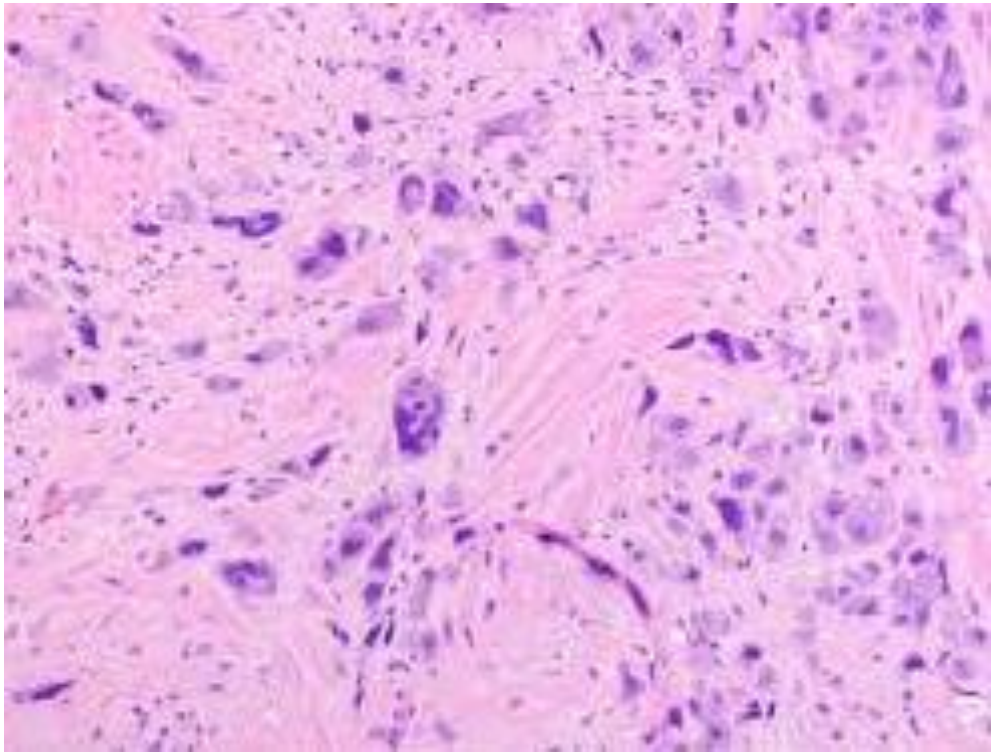

- 1.what is the striking feature you notice in the section?
- 2.Mention your differential diagnoses?
- 3.what histological features you need to look for narrow down your DDs?
- What clinical information your require?
- What is the most useful immunomarker you would do?

- 1.Mononucleated and multinucleated trophoblasts infiltrating myometrial fibres.
- 2.EPS

  PSTT
- 3.Presence of cohesive sheets, mitoses, vascular invasion.
- 4.uss-presence of mass lesion.
- 5.Ki 67

Exaggerated placental site(EPS)

- Represents part of the spectrum of normal implantation site reaction.
- Characterized by exuberant infiltration of the myometrium by IT
- Is associated with normal gestation or hydatidiform mole.

Microscopy

- Extensive infiltration of the endomerium and the myomerium by IT, many are multinucleated.
- Overall arhcitecture of the placental site-not disturbed.
- No necrosis, no mitotic activity
- Cells-hyperchromatic irregular nuclei, abundant eosinophilic cytoplasm.
- IHC- as in PSTT(Mel-CAM,hPL,CK positive)

  ki 67 near zero

Discussion

TROPHOBLAST

- Trophoblast are derived from?

from conceptus

not maternal

Trophoblast cont…

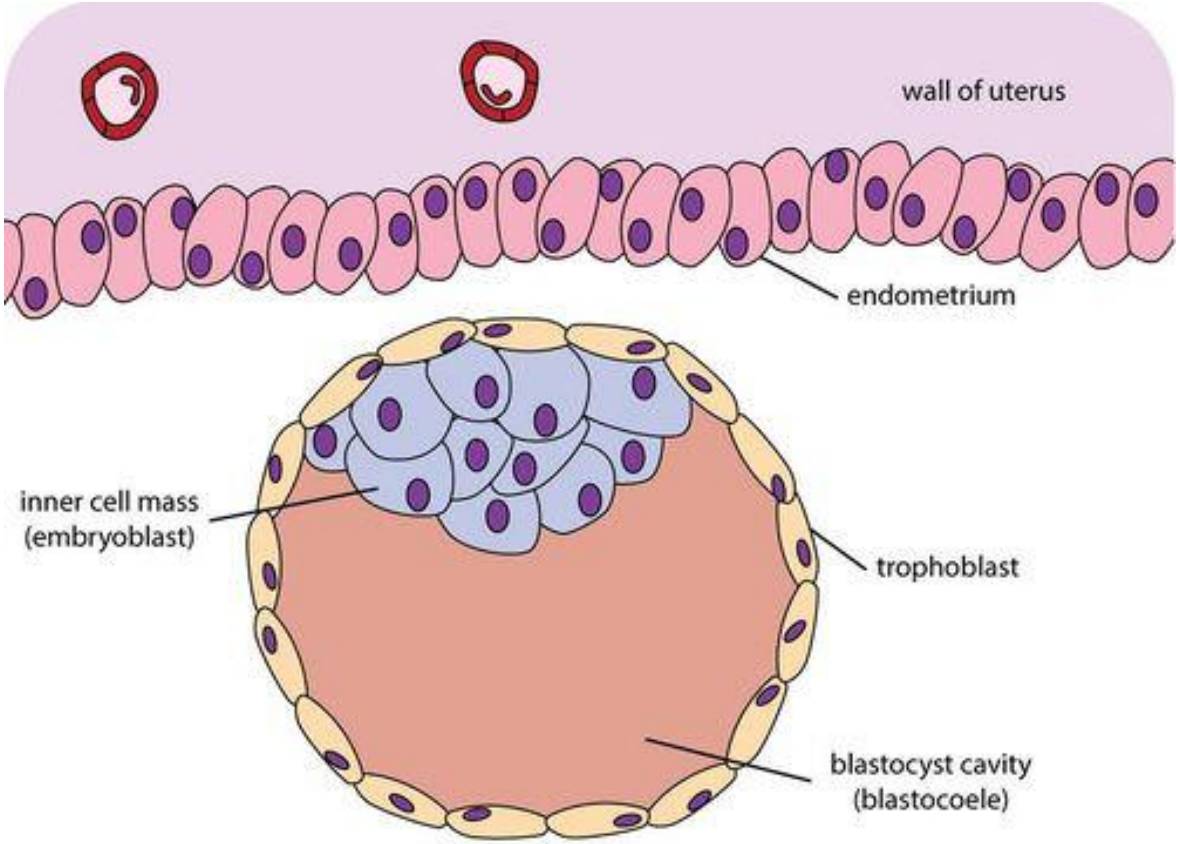

- Tropho –nourishment,food ;blasto-sprout
- Composed of different subpopulation of cells
- 1. cytotrophoblast (CT)- stem cell
- 2. syncytiotrophoblast(ST)- terminally differentiated cell
- 3. intermediate trophoblast(IT)- shares some of the morphologic and functional features of both cytotrophoblast and syncytiotrophoblast

Trophoblast cont..

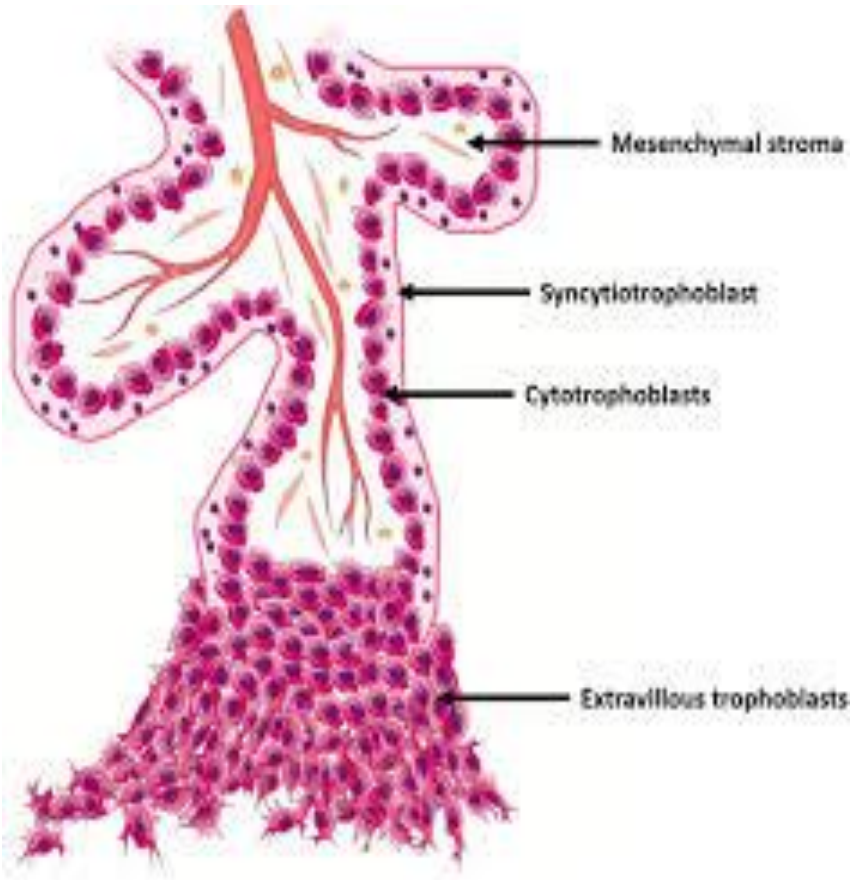

- Villous trophoblast-

  -surface of the chorionic villi

  - CT,ST, small amount of IT

- Extravillous trophoblast-

  -locations other than surface of the chorionic villi

  - IT

CYTOTROPHOBLAST (langhans cells)

- Small and uniform, polygonal to oval shape cell
- Distinct cell border
- Single round to oval nucleus
- Cytoplasm –clear or granular

- Forms an inner layer on the surface of the chorionic villi

CT cont..

- Represents stem cell-Ki 67 index 25-50%(highest in early stage of pregnancy)
- Does not produce hormones- negative for placental hormones
- Able to differentiate along 2 pathways

  1.on villous surface fused to form ST

  2. in extavillous areas in to IT

SYNCYTIOTROPHOBLAST

- Large multinucleated cell
- Abundant eosinophilic to amphophilic vacuolated cytoplasm
- Multiple dark often pyknotic nuclei
- EM-apical surface has elongated microvilli(to increase the surface area),pinocytotic vesicles in subapical cytoplasm
- Overlies CT in chorionic villi

ST cont….

- Responsible for respiratory gases,nutrients and waste product exchange between mother and fetus
- Production of placental hormones

hCG,hPL,PLAP, alfa-inhibin,placental growth hormones,estradiol and progesterone

. Proliferative index Ki 67 is negative

INTERMEDIATE TROPHOBLAST

- Heterogeneous cell population with different features.
- 1.villous intermediate trophoblast
- 2.implantation site intermediate trophoblast
- 3.chorionic type intermediate trophoblast

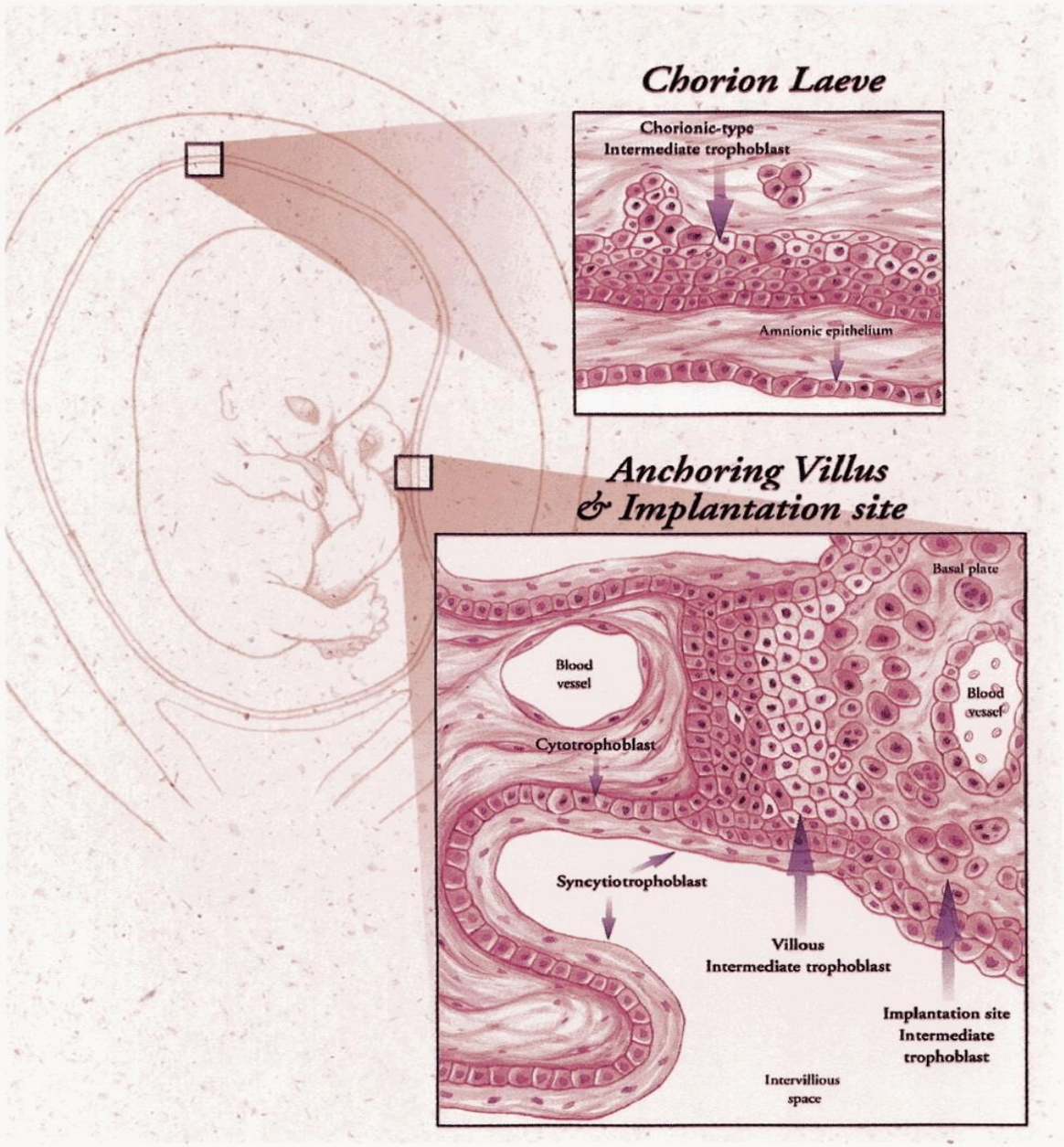
Chorion Laeve
Chorionic-type
Intermediate trophoblast
Amnionic epithelium
Anchoring Villus
& Implantation site
Basal plate
Blood
vessel
Blood
vessel
Cytotrophoblast
Syncytiotrophoblast
Villous
Intermediate trophoblast
Implantation site
Intermediate
trophoblast
Intervillious
space

IT cont..

- Villous intermediate trophoblast-

  larger than CT

  single uniform nucleus, pale cytoplasm

  localized in the trophoblastic columns of anchoring villi

  Ki 67 positive,inhibin alfa -negative

- Implantation site intermediate trophoblast

  appearance varies according to its location

  shape –polygonal/oval in endometrium,spindle shape in myometrium

  mononucleated/multinucleated cell

  abundant eosinophilic to amphophilic cytoplasm

  nuclei- irregular outline, lobated with multiple deep clefts

- Implantation site IT cont…

function-modification of maternal spiral arteries in the basal plate and establishment of the materno-fetal circulation

express new adhesion molecules-Mel-CAM(melanoma cell adhesion molecule/CD146)

its ligand on smooth muscle cells of the myometrium

- Invade in to the spiral arterial wall-fibrinoid meterial deposition, replace endothelial cells (by acquisition of endothelial markers)
- result modification in to low resistance vascular channel with a large calibre.

- Produce placental hormones in variable amounts
- No proliferative activity
- IHC- diffuse Mel-CAM,inhibin alfa and hPL positivity
- Focal hCG positivity
- Ki 67 negative
- P63 negative

- Chorionic type IT

  mononucleated/multinucleated cell

  eosinophilic to clear cytoplasm

  located in the chorion laeve of placental membrane

- Function- production of extracellular matrix which supplies elasticity and strength to the fetal membrane
- Have mitotic activity-Ki 67 3-10%
- p63,PLAP diffusely positive
- Mel-CAM,hPL focally positive

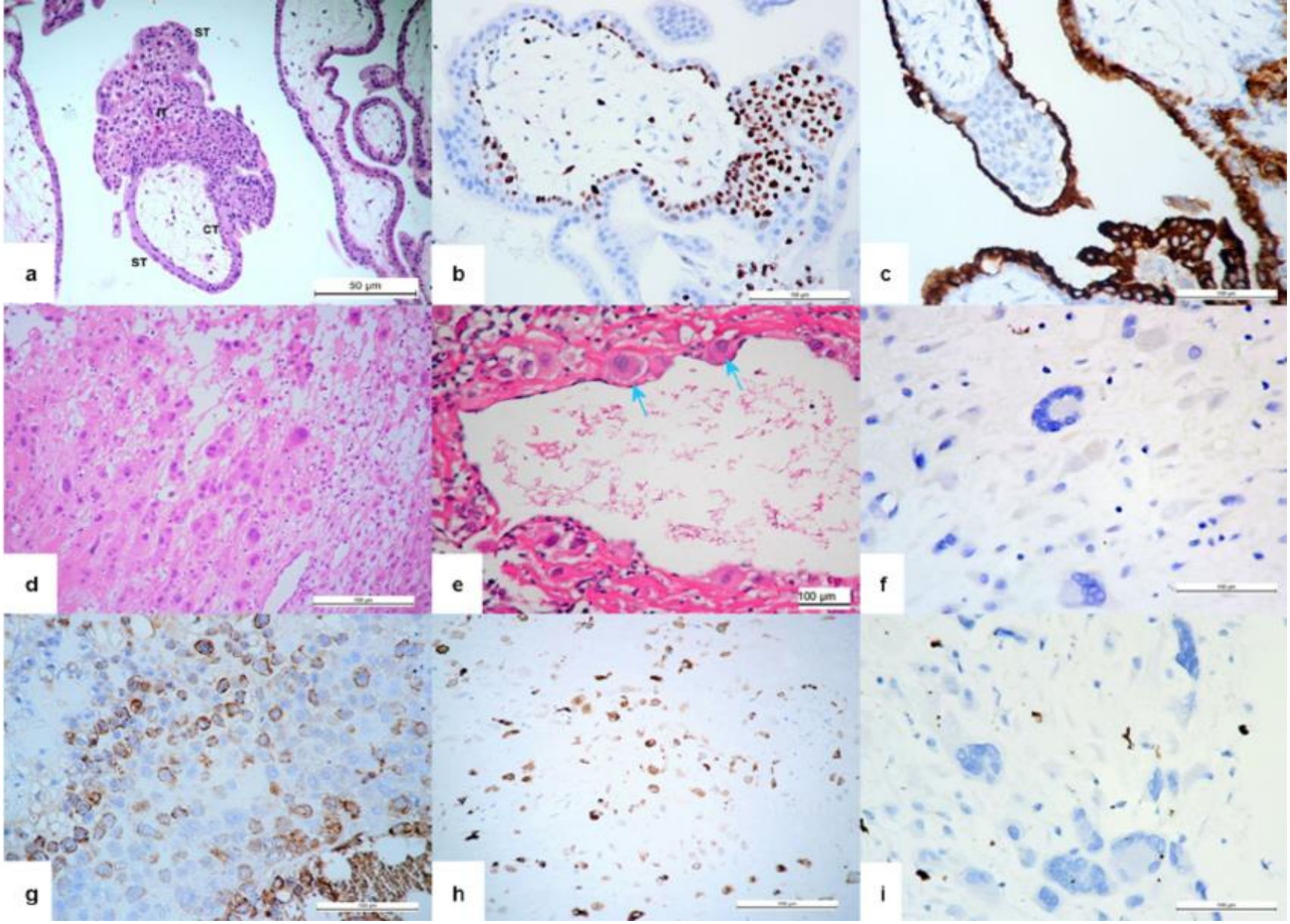

a- placental villous, b-ki 67 ,c-inhibin alfa,d-implantation site IT, e-infiltration of spiral arteries by implantation site IT ,f-p63 ,g-hPL ,h- inhibin alfa ,i-ki 67 negativity in implantation site IT

	CT	ST	Villous IT	Implantation site IT	Chorionic type IT
morphology	Round,small cell,scant clear to granular cytoplasm,prominent cell borders	Multinucleated large cell,abundant vaculated cytoplasm	Larger than CT, single round nucleus, pale cytoplasm	Multinucleated/mononucleated,abundant cytoplasm, nuclei-lobated	Mono/multinucleated,round to polyhedral, clear to eosinophilic cytoplasm
Growth pattern	cohesive	syncytial	cohesive	infiltrating	cohesive
IHC	CK	CK,hCG,hPL, PLAP, inhibin	CK,	CK, Mel-CAM,inhibin ,hPL, focal hCG	CK,p63,PLAP diffusely ,Mel-CAM and ,hPL focally
Ki 67	25-50%	0	>90%	0	3-10%
Associated lesions	choriocarcinoma	choriocarcinoma		EPS PSTT	PSN ETT

MCQ

- T/F regarding IT
- 1. CT differentiate in to IT.
- 2.The main function of IT is to secrete placental hormones.
- 3.Cytokeratins are positive in all 3 types of IT
- 4.Any proliferative activity in the implantation site IT should be considered abnormal.
- 5.PSTT arises from chorionic type IT.

Placental site trophoblastic tumour

- A trophoblastic tumour consisting of neoplastic implantation site IT.
- Occur in women ranging in age from 20-63 yrs
- 2/3 of cases follow a full term pregnancy.
- Beta-hCG levels are mildly elevated.(<1000mIU/ml).
- Macroscopy-polypoid extending to the uterine cavity/endophytic myometrial growth.

cut surface-soft and tan,areas of h'age and necrosis

Microscopy

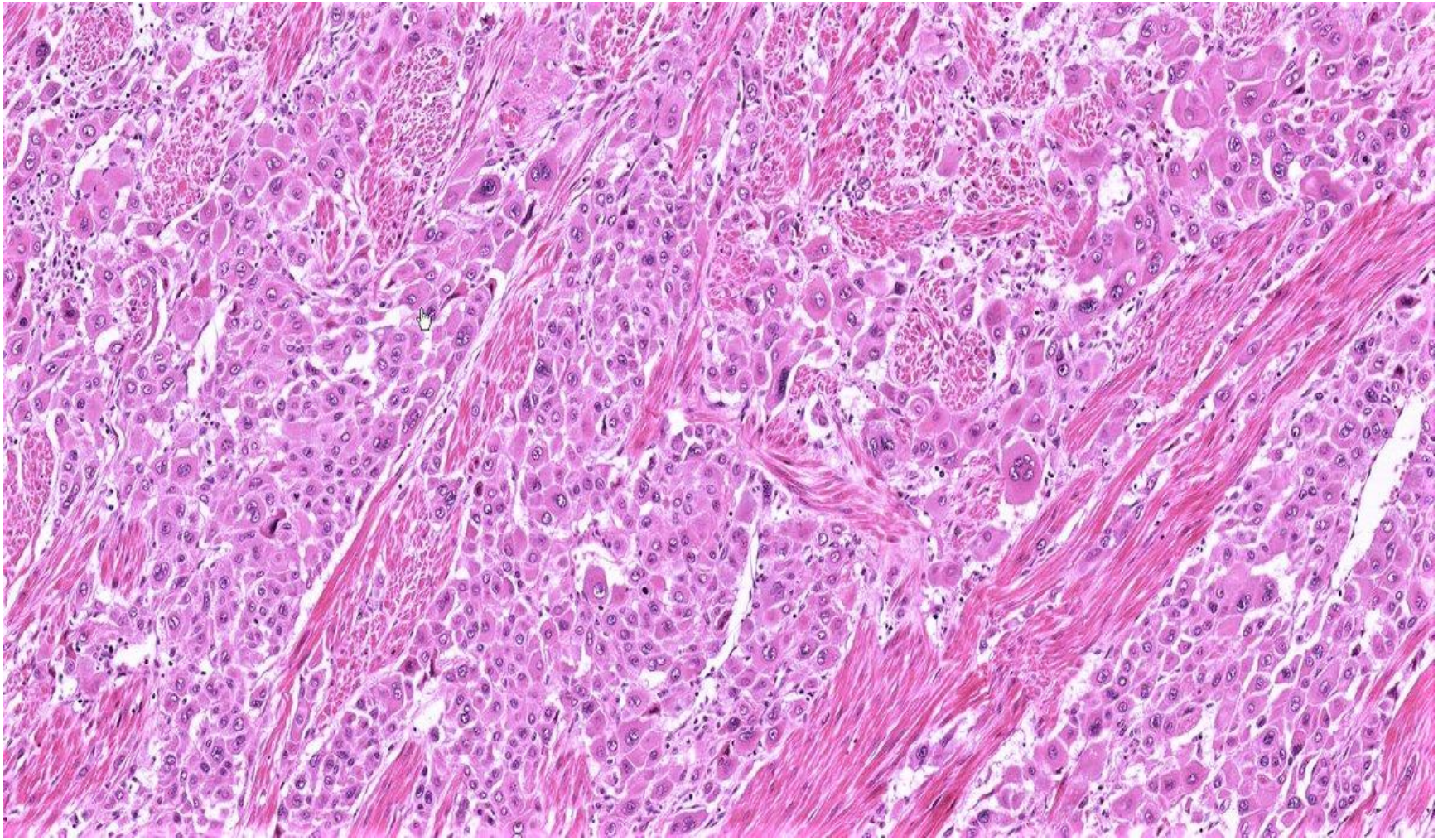

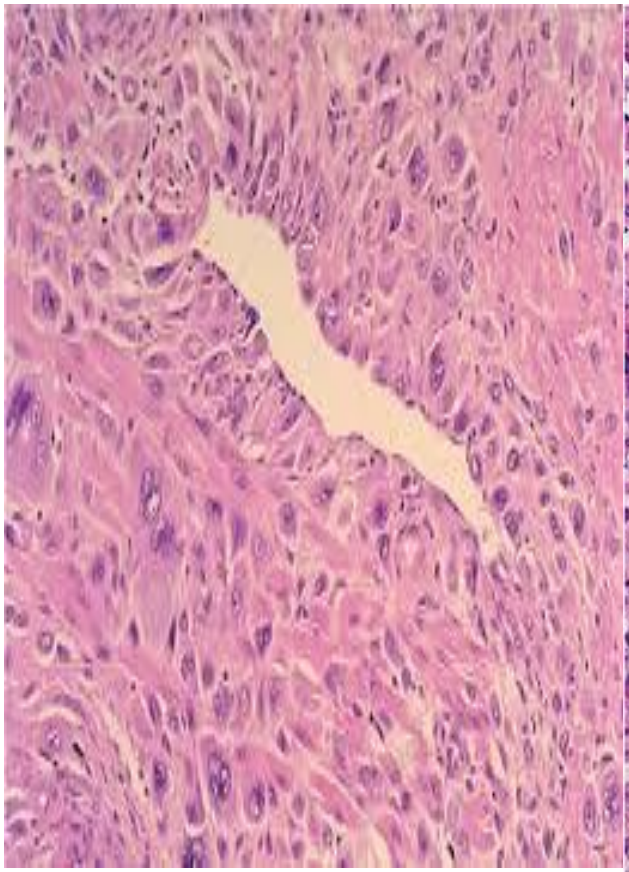

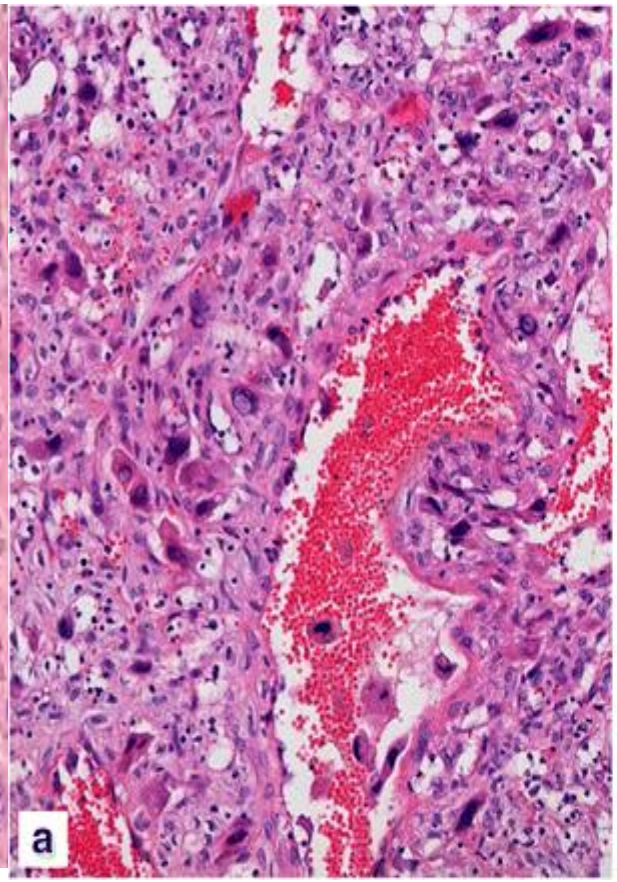
a

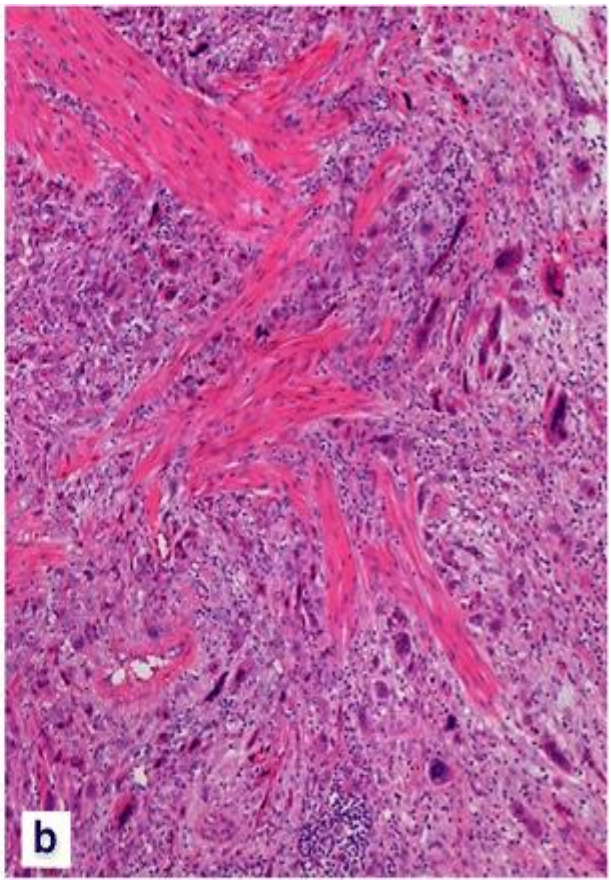
b

Microscopy

- Sheets of polygonal to spindle neoplastic IT cells.
- At the periphery,cords or singly scattered tumour cells infiltrate muscle fibres of the myometrium.
- Tumour cells-large convoluted, hyperchromatic nuclei, eosinophilic to clear cytoplasm.
- Characteristic form of vascular invasion-Blood vessel walls are extensively replaced by trophoblastic cells and fibrinoid meterial.
- Presence of necrosis indicative of malignant behavior.
- Villi are not identified.

IHC

- Diffusely express-Mel-CAM,CK,HSD3B1,hPL,MUC4.
- Focal expression-hCG
- Ki67-10-30%
- DDs
  1. EPS
  2. choriocarcinoma
  3. ETT

Prognosis

Treatment- simple hysterectomy ,chemotherapy

Most cured by simple hysterectomy

25-30%- recurrent disease

Some metastasize-lung,liver,brain

Epithelioid trophoblastic tumour

- A trophoblastic tumour consisting of neoplastic chorionic-type intermediate trophoblast.
- Rare
- Usually occur in women of reproductive age
- Usually seen after normal term pregnancy,but occur following any pregnancy event
- Mild to moderate elevation of serum hCG

- Gross –

Discrete nodule or cystic hemorrhagic masses deeply infiltrating the surrounding structures

cut surface –white to tan brown with hemorrhages and necrosis.

common locations-lower uterine segment,cervix

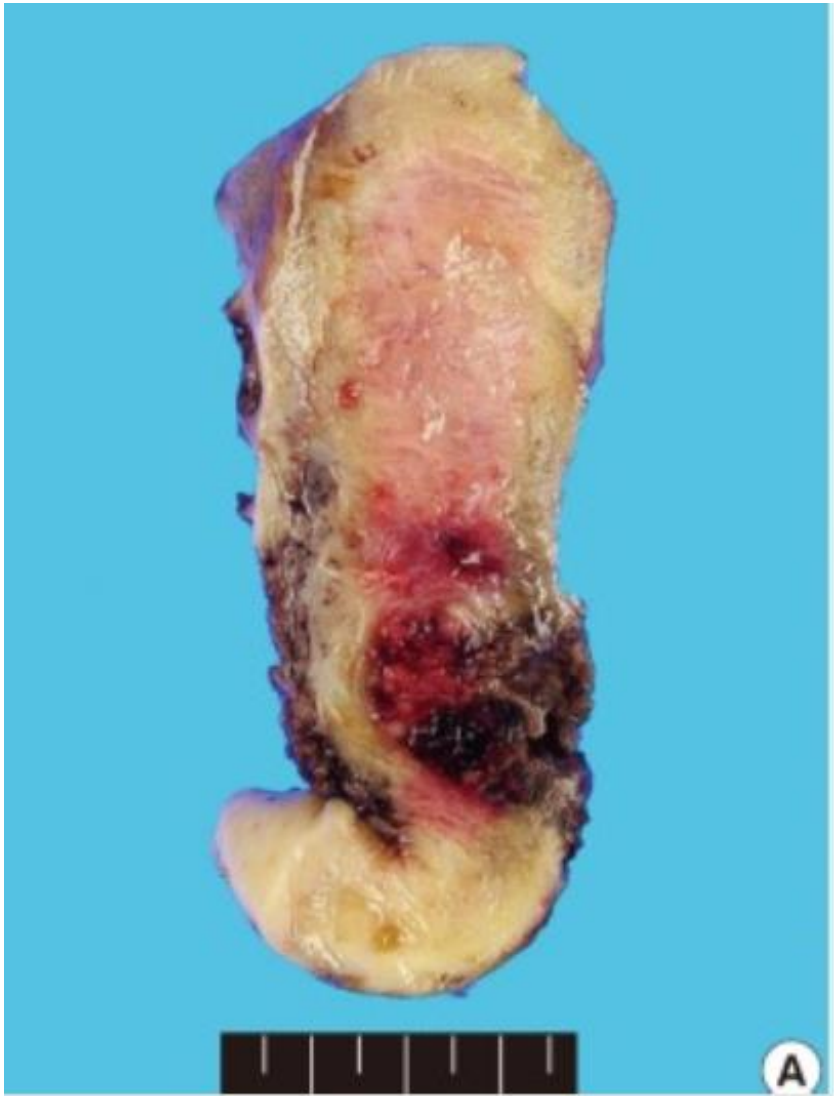

- Nodular and well circumscribed, focally infiltrative at the periphery
- Tumour cells arranged as nests /cord/large masses.
- Tumour cell nests intimately associated with an eosinophilic, fibrillar, hyaline like meterial.
- Extensive geographic necrosis
- Calcification is common.
- Tumour cells-uniform population of mononucleated cells,round nuclei with distinct nucleoli,moderate eosinophilic to clear cytoplasm with distinct cell membrane.
- ETT can replace the surface endocervical epithelium and endomerial surface epithelium,mimic squamous epithelium

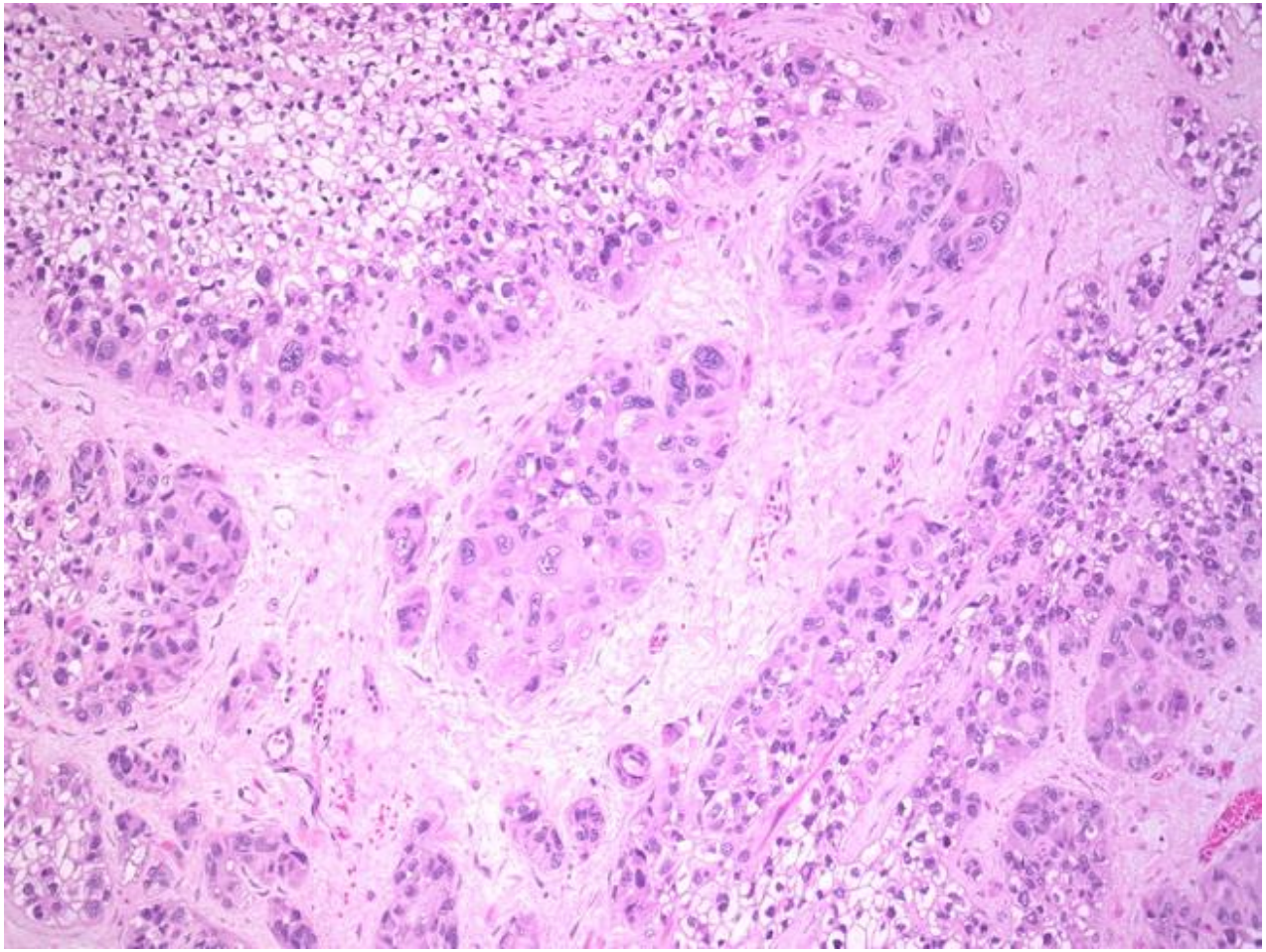

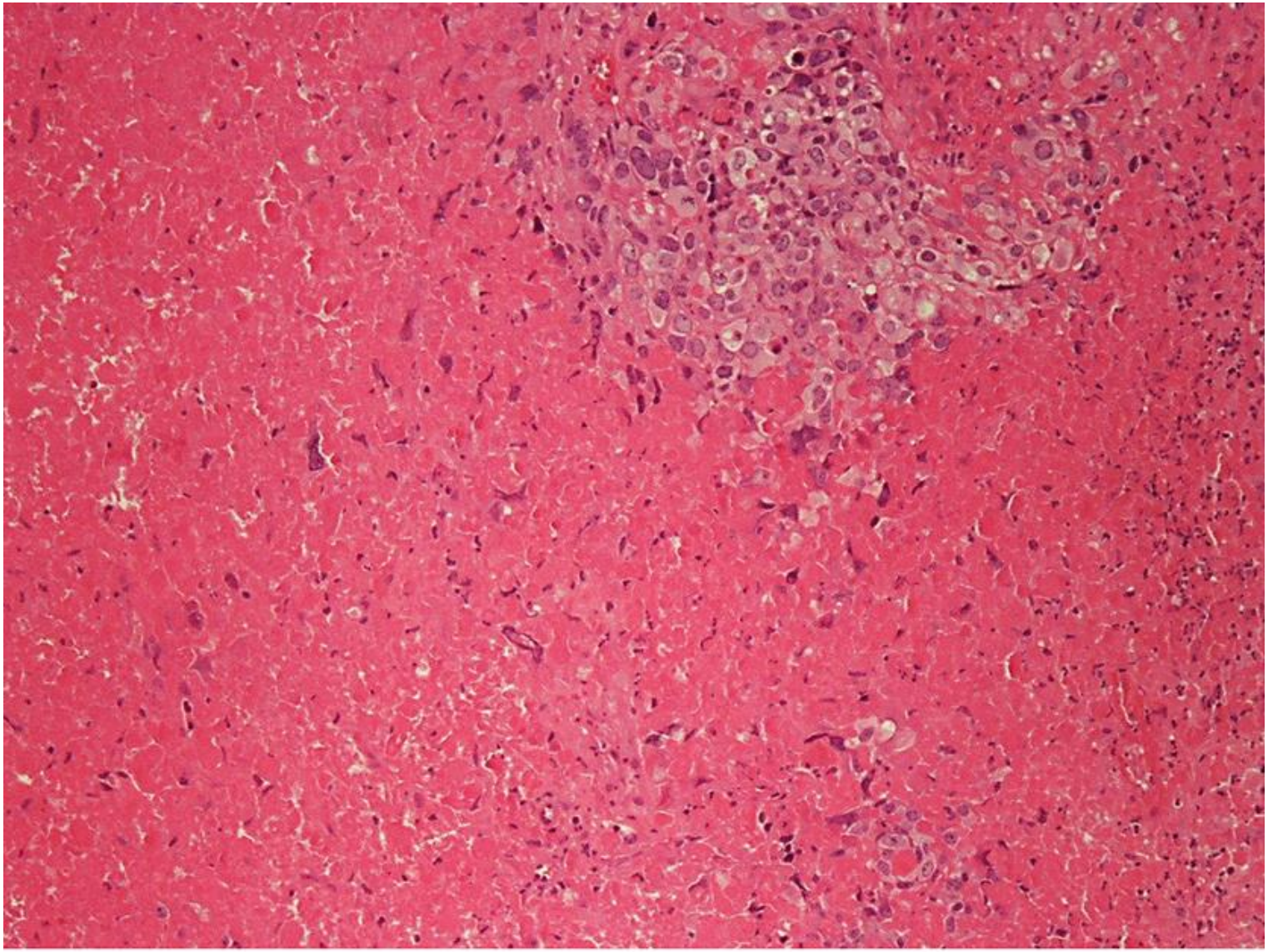

Mononucleate intermediate trophoblasts surrounded by extensive necrosis, hyaline like matrix resembling keratinous material in squamous cell carcinoma

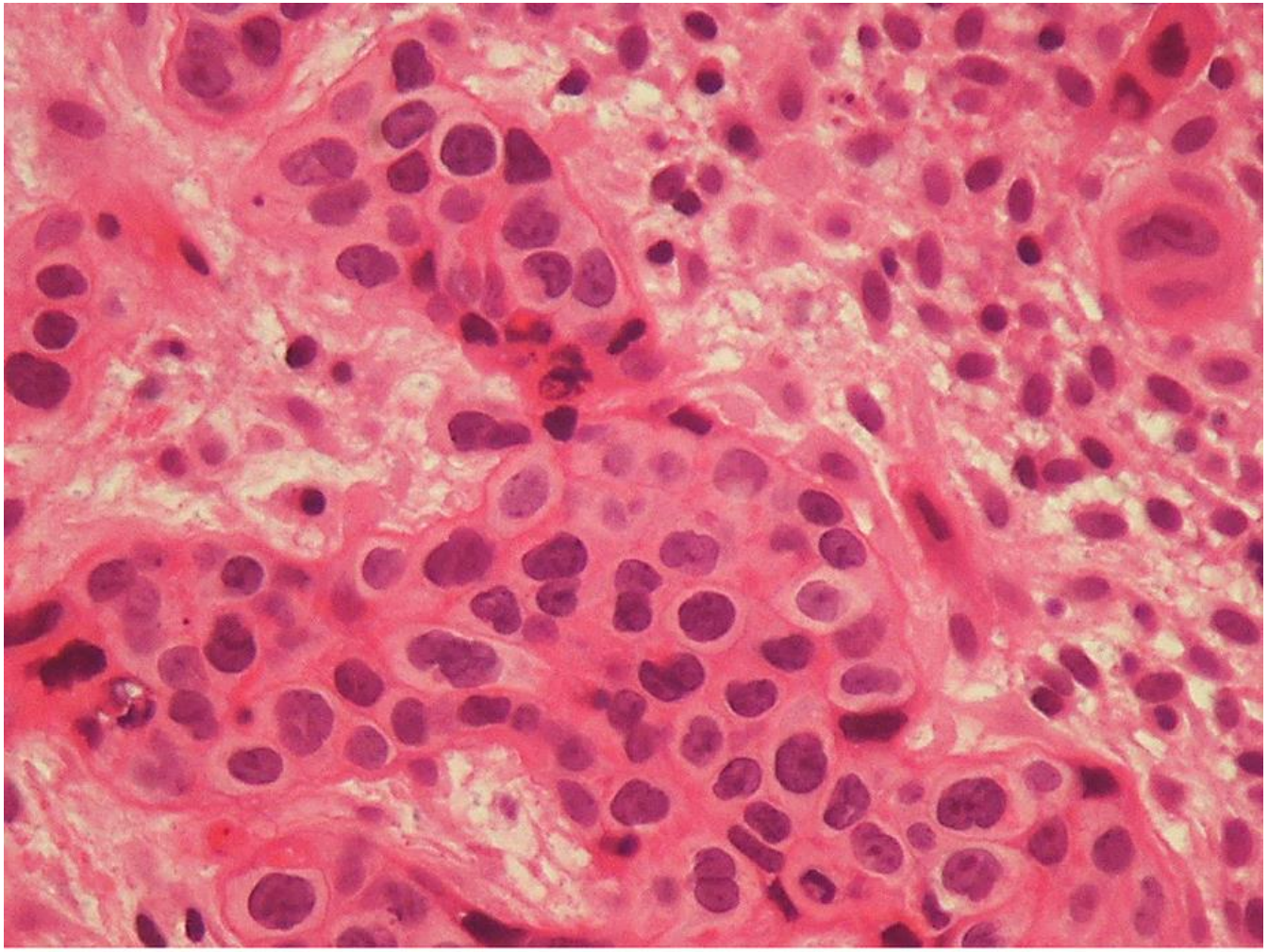

The mononucleate trophoblasts have medium to large, round to oval nuclei, eosinophilic to clear cytoplasm with variable nuclear pleomorphism

IHC

- Diffuse expression of p63,inhibin,HSD3B1,GATA3,Cyclin E
- Focally express-Mel-CAM and hPL
- Ki 67 is >10%

- Prognosis-
- Like PSTT, metastasis in 25% of cases
- DDs
- 1.PSTT-infiltrative border, cells are larger, necrosis,calcification not seen,characteristic vascular invasion.IHC-hPL,Mel-CAM positive, p63 -negative
- 2.PSN- microscopic,less cellular, bland cytology,mitotic activity low, ki67<10%
- 3.choriocarcinoma-3 populations of cells
- 4.Keratinizing SCC of cervix- IHC-CK 18 –ve, CK 5/6,p16 +ve

- Molar pregnancies-
  hydatidiform mole:complete
  partial
  invasive
- Gestational trophoblastic neoplasia-
  Choriocarcinoma
  Placental site trophoblastic tumour(PSTT)
  Epithelioid trophoblastic tumour(ETT)
- Non neoplastic trophoblastic lesions-
  Exaggerated placental site(EPS)
  Placental site nodule and plaque(PSN)

Placental site nodule and plaque

- A benign well circumscribed nodule or plaque with abundant hyalinized stroma containing chorionic-type IT.
- Nodular ,size-4-10 mm
- Incidental finding.

- Circumscribed nodule or plaque of hyalinized extracellular matrix
- Haphazardly distributed chorionic type IT.
- Cells-many cells-small uniform nuclei with clear cytoplasm,some have large,irregular hyperchromatic nuclei with abandant eosinophilic cytoplasm.
- Mitoses rare
- IHC-low ki 67<8%,p63 +ve

cyclin E –ve .

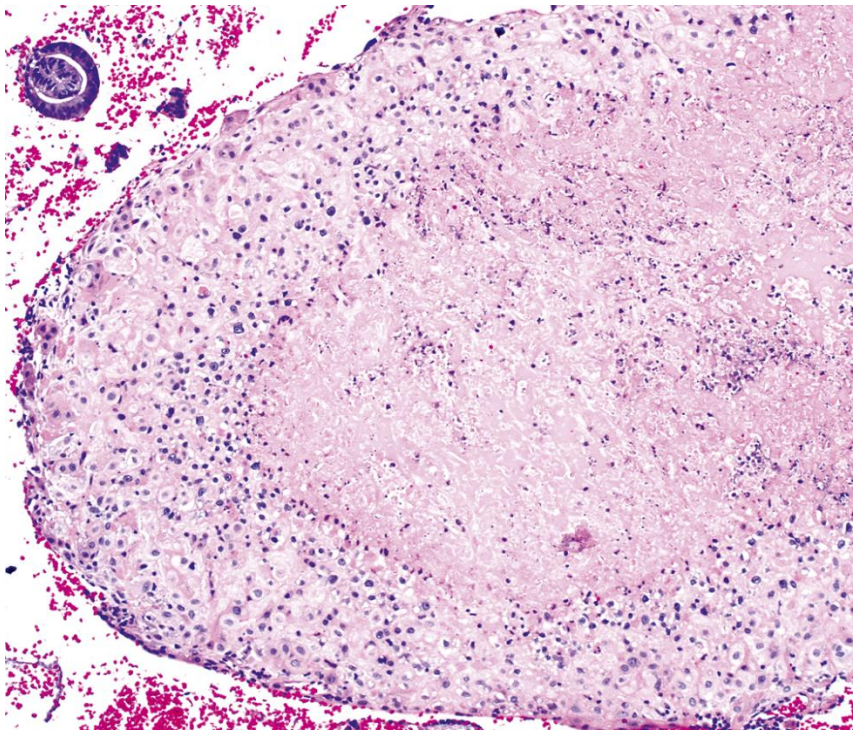

Thank
you!!