

National Guidelines in Histopathology

# Handling & reporting of Carcinoma of the Breast

Second edition  
2021



Ministry of Health, Sri Lanka  
and College of Pathologists of Sri Lanka



# **National Guidelines in Histopathology**

## **Handling & Reporting of Carcinoma of the Breast**

Second edition, 2021

Content editors of this book: The Breast Guidelines Technical Committee

Series editors, National Guidelines in Histopathology, second edition:

Dilani Lokuhetty, Isha Prematilleke

© College of Pathologists of Sri Lanka, 2021

Published online by Ministry of Health, Sri Lanka

ISBN 978-624-6147-00-6

This work is copyright. You may download, display, print and reproduce this document for your personal, non-commercial use. Requests and inquiries concerning reproduction and rights should be addressed to The College of Pathologists of Sri Lanka at [colpathsl@yahoo.com](mailto:colpathsl@yahoo.com).

First published: 2007



**Message by the Director General, Health Services  
Ministry of Health, Sri Lanka**

Cancer is one of the leading non-communicable diseases in Sri Lanka. With the establishment of national cancer policy on cancer prevention and control, there has been a commendable improvement in the cancer services provided island-wide.

The pathologists play a major role in the diagnosis of cancer and it is of utmost importance to formulate new guidelines as well as to update existing guidelines to improve the quality of diagnosis and to predict the prognosis of the disease in cancer patients.

These guidelines on handling tumours of the gastrointestinal tract, breast and gynaecological region as well as the guidelines on specimen handling and transport appear to be comprehensive guides to the histopathologists practicing in Sri Lanka and hope that these guidelines will help to improve the quality and the consistency of the histopathology reports across the country.

I am very grateful to the College of Pathologists of Sri Lanka for having identified the need and have been able to accomplish this difficult task amidst many hardships faced during the Covid-19 pandemic. I wish to thank the editors, authors and the clinicians who have contributed to these guidelines for their commitment in formulating these guidelines.

As these guidelines will be available in a freely available, easy to use, electronic format and I hope that these will help to improve the quality and delivery of diagnostic services to cancer patients in Sri Lanka.

I wish the College of Pathologists of Sri Lanka all the success in their future endeavours to improve the quality of histopathology services in the country.

**Dr. Asela Gunawardena**

Director General of Health Services

Ministry of Health

Sri Lanka



**Message by the Deputy Director General  
Laboratory Services  
Ministry of Health, Sri Lanka**

In the provision of health care services, the laboratory sector plays a vital role by providing timely and accurate test results enabling the clinicians in diagnosis and treatment. Cancer is one of the leading health issues in Sri Lanka which needs effective curative and preventive diagnostic services. In order to achieve this, the contribution of histopathologists is invaluable.

The Laboratory Services Unit, Ministry of Health works with a vision to achieve standards for medical laboratories set by the international organizations for standardization and a mission to provide timely, reliable, high-quality diagnostic services to relevant health care providers. These guidelines published by the College of Pathologists, Sri Lanka have given a valuable contribution to achieving our mission and improving the services provided by the histopathology laboratories to the public.

I am pleased to note that the availability of these guidelines in electronic format hence histopathologists working all over the country will be able to get the maximum use of it.

I wish the College of Histopathologists, Sri Lanka all the success in their future endeavors to provide a tremendous service to uplift the health of the citizens in Sri Lanka.

**Dr. Sudath K. Dharmaratne**

Deputy Director General-Laboratory Services  
Ministry of Health  
Sri Lanka



## Message by the President College of Pathologists of Sri Lanka

Since the first series of the National Guidelines in Histopathology were published in 2007, the necessity to revise these guidelines and formulate new guidelines was considered to keep pace with the rapid advancements occurring in the field of histopathology worldwide. The College of Pathologists has been able to complete and publish this new series of guidelines with the objective of improving the diagnostic services in histopathology and histopathology reporting across the country. I am extremely happy that we were able to accomplish this task during the Covid-19 pandemic, utilizing the lockdown periods effectively.

The guidelines have been formulated after extensive discussion by the members of the guideline committees and clinicians in the relevant fields, conforming to the latest, accepted international guidelines in histopathology reporting. These offer a comprehensive guide to the pathologists when handling tumours of the gastrointestinal tract, breast and genaealogical region as well as to specimen handling and transport.

**The structure of the guidelines has been made similar to the first series wherever possible with X, Y and Z denoting the mandatory, desirable and optional recommendations respectively. (X; Mandatory; recommendations that can be carried out in most of the institutions in Sri Lanka, Y; Desirable; investigations that can be carried out in selected institutions in Sri Lanka including the private sector and Z; Optional; investigations that are not freely available in Sri Lanka which may be performed in the private sector or abroad).**

The guidelines will be in the electronic format to allow maximum visibility to the histopathologists working across the country.

On behalf of the College of pathologists of Sri Lanka, I wish to acknowledge the contributions made by the series editors, content editors, authours, clinicians and all the members of the guideline committees and thank them for their commitment to formulate these guidelines to be on par with international guidelines.

I am also grateful to the Director General of Health Services Dr. Asela Gunawardena and the Deputy Director General Laboratory Services, Dr. Sudath Dharmaratne for facilitating the electronic publication process of these guidelines.

I hope that the histopathologists working across the country will make full use of these guidelines to improve the quality of diagnostic services and reporting in histopathology.

**Prof. Dulani Beneragama**

President, College of Pathologists of Sri Lanka, 2021.

## Technical Committee

Chairperson	Dr Renuka Goonesinghe
Conveners	Dr Udani Kiriwandeniya Dr Harshima Wijesinghe
Members	Prof Chandu de Silva Prof Dilani Lokuhetty Dr Janakie Fernando Dr Kamani Samarasinghe Dr Modini Jayawickrama Dr Nilmini Perera Dr Ineesha Jayasinghe Dr Nayana Ratnayake Dr Chandrani Somaratne Dr MKL Manjula Dr Shirani Samarathunga

## Clinical contributors

---

<b>Consultant Oncosurgeons</b>	Dr Kanishka De Silva Dr Mahanada Udukala Dr A Parthipan
<b>Consultant Oncologists</b>	Dr Sujeewa Weerasinghe Dr Umagawri Sarawanamuttu
<b>Consultant Radiologists</b>	Dr Uditha Kumarasena Dr Wijelal Meegoda

**Overview**

Dilani Lokuhetty

<b>Chapter 1</b>	<b>Clinician's role in optimizing reporting of breast specimens</b>	The Breast Guidelines Technical Committee
<b>Chapter 2</b>	<b>Handling and reporting of core needle biopsy and vacuum assisted biopsy specimens</b>	Nilmini Perera Udani Kiriwandeniya
<b>Chapter 3</b>	<b>Handling and reporting of excision and mastectomy specimens</b>	Janakie Fernando Modini Jayawickrema M K L Manjula Shirani Samarathunga
<b>Chapter 4</b>	<b>Handling and reporting of therapeutic excision and mastectomy specimens after neoadjuvant chemotherapy</b>	Kamani Samarasinghe Chandrani Somaratne
<b>Chapter 5</b>	<b>Handling and reporting of axillary clearance specimens</b>	Chandu de Silva Nayana Ratnayake
<b>Chapter 6</b>	<b>Handling and reporting of sentinel node biopsy in early breast cancer</b>	Chandu de Silva Nayana Ratnayake
<b>Chapter 7</b>	<b>Reporting of biomarkers</b>	Renuka Goonesinghe Ineesha Jayasinghe
<b>Chapter 8</b>	<b>Other ancillary tests</b>	Harshima Wijesinghe

**Illustrations**

Dr MKL Manjula

## CONTENTS

Topic	Page
<b>Overview</b>	1
<b>Chapter 1</b> Clinician's role in optimizing reporting of breast specimens	4
<b>Chapter 2</b> Handling and reporting of core needle biopsy and vacuum assisted biopsy specimens	9
<b>Chapter 3</b> Handling and reporting of excision and mastectomy specimens	13
<b>Chapter 4</b> Handling and reporting of therapeutic excision and mastectomy specimens after neoadjuvant chemotherapy	34
<b>Chapter 5</b> Handling and reporting of axillary clearance specimens	41
<b>Chapter 6</b> Handling and reporting of sentinel lymph node biopsy in early breast cancer	44
<b>Chapter 7</b> Reporting of biomarkers	47
<b>Chapter 8</b> Other ancillary tests	54
<b>Annexures</b>	
I.    Sample requisition form	55
II.    Checklist to be filled before sending the specimen from the surgical theatre	56
III.    World Health Organization classification of breast carcinoma	56
IV.    Breast cancer grading	59
V.    Nuclear grade of ductal carcinoma in situ	62
VI.    Guideline for assessment of tumour infiltrating lymphocytes	63
VII.    American Joint Committee in Cancer (AJCC) Staging	64
VIII.    Residual Cancer Burden (RCB) Calculator	68
IX.    Proformas for reporting	69



## OVERVIEW

---

Breast cancer is the most common cancer in women worldwide. Based on global cancer observatory (Globocan) data, breast cancer has an age adjusted standardized rate (ASR) of 46.3 per 100,000 population. The incidence rates vary nearly four-fold across the world regions, with South and Central Asia having a lower incidence compared to more developed countries. Globally, the mortality rate from breast cancer is at an ASR of 13.0 per 100,000 population. Although the incidence of breast cancer is significantly higher in high income countries, the mortality rate is lower, due to the early stage at presentation. Low-income countries have a lower incidence, however with a higher mortality rate, mostly due to late presentation of the disease.

According to the National Cancer Control Programme (2014), breast cancer tops the list of cancers affecting Sri Lankan women, with an age standardized rate of 23 per 100,000 population. A gradual but significant increase in the incidence of female breast cancer is observed in Sri Lanka, particularly amongst postmenopausal women with the age standardized rates of female breast cancer in Sri Lanka increasing from 17.3 per 100,000 in 2001 to 24.7 per 100,000 in 2010. The lifetime risk of developing breast cancer is 2.5% for a Sri Lankan woman. Furthermore, it is the commonest cancer among local women in the age groups of 35-49, 50-64 and 65 years and above.

Surgical specimens of breast cancer are therefore a common specimen encountered in the local pathology laboratories. The type of surgical specimens received have shifted more towards smaller specimens (core needle biopsy, vacuum assisted biopsy, wide local excision, quadrantectomy) over the years in addition to the mastectomy specimens (modified radical and simple mastectomies), that are yet received. Additionally, instead of the axillary dissection specimens, more sentinel lymph nodes are received for evaluation of metastasis. Sentinel lymph nodes are increasingly sent for evaluation as frozen sections during the surgical procedure to decide on the requirement for axillary dissection. The correct handling of all these gross specimens is a mandatory prerequisite for providing a good pathology report encompassing all the prognostic and predictive information required for post-surgical management of breast cancer patients. The prognostic and predictive information required include histological features (tumour type, tumour grade, lympho-vascular status, tumour infiltrating lymphocytes, margin status, pathological tumour stage) as well the biomarker

status of the tumour (hormone receptor and HER2 expression) and the proliferative activity (Ki67 index) assessed by immunohistochemical assay.

These guidelines aim to objectively lay down the process of breast surgical specimen handling in the pathology laboratory in the current setting, minimizing the pre-analytical and analytical errors that could impact the information that is to be provided in the pathology report. Guidelines also lay down the pathology information that is required to be provided in the pathology report in synoptic format, to guide the pathologist and the young pathology trainees in their busy practice. This is a timely endeavour as the previous guidelines for breast surgical specimens were developed fourteen years ago in 2007. Since then, in addition to the shift in the type of specimens received, defining the biomarker status of the breast cancer has become essential. With the development of central and regional immunohistochemistry laboratories in Colombo and at regional level, assessing the biomarker status of breast cancers has now become a reality. In addition to the pre-analytical requirements, guidelines on interpretation of the biomarker status and the requirement for further assays (fluorescent in situ hybridization) are provided. Although facilities for gene expression are currently not available in the local setting, they may provide additional prognostic and/or predictive information to complement pathology assessment and predict the benefit of adjuvant chemotherapy. They have been outlined briefly.

A section is also dedicated to the surgeons providing guidance on pre-laboratory specimen handling. This hopefully would help to maintain the preservation of the tumour and thereby reduce the pre-analytical errors associated with assessment of tumour typing, tumour grading, lymphovascular status and bio-marker status which are impacted by the cold ischaemia time.

The guidelines developed are applicable to all pathology laboratories and pathologists are encouraged to adhere to these guidelines. The recommendations are divided into three levels based on the facilities available in the pathology laboratories in the local setting. They are as follows:

- X - Mandatory
- Y - Desirable
- Z – Optional

If requests are made by the clinician/patient for investigations that are not available in the local setting it would be appropriate to plan to send tissue blocks/slides/pathology reports to an overseas centre capable of performing these tests. Pathologists are encouraged to discuss with the respective surgeon/oncologist in this regard.

It is hoped that these guidelines will make pathology reporting of breast cancer more uniform across the laboratories in the country and provide guidance on management and prognostication of cancers.

**Prof. Dilani Lokuhetty**

Chairperson, Committee to formulate National Guidelines in Histopathology on Breast Malignancies, 2<sup>nd</sup> edition.

**References**

1. Bray F, Ferlay J, Soerjomataram I, Siegel RL, Torre LA, Jemal A. Global Cancer Statistics 2018: GLOBOCAN Estimates of Incidence and Mortality Worldwide for 36 Cancers in 185 Countries. *A CANCER J CLIN* 2018;68:394–424. doi: 10.3322/caac.21492.
2. National Cancer Control Programme Sri Lanka. Cancer Incidence Data, Sri Lanka 2014.

## CHAPTER 1

# Clinician's role in optimizing reporting of breast specimens

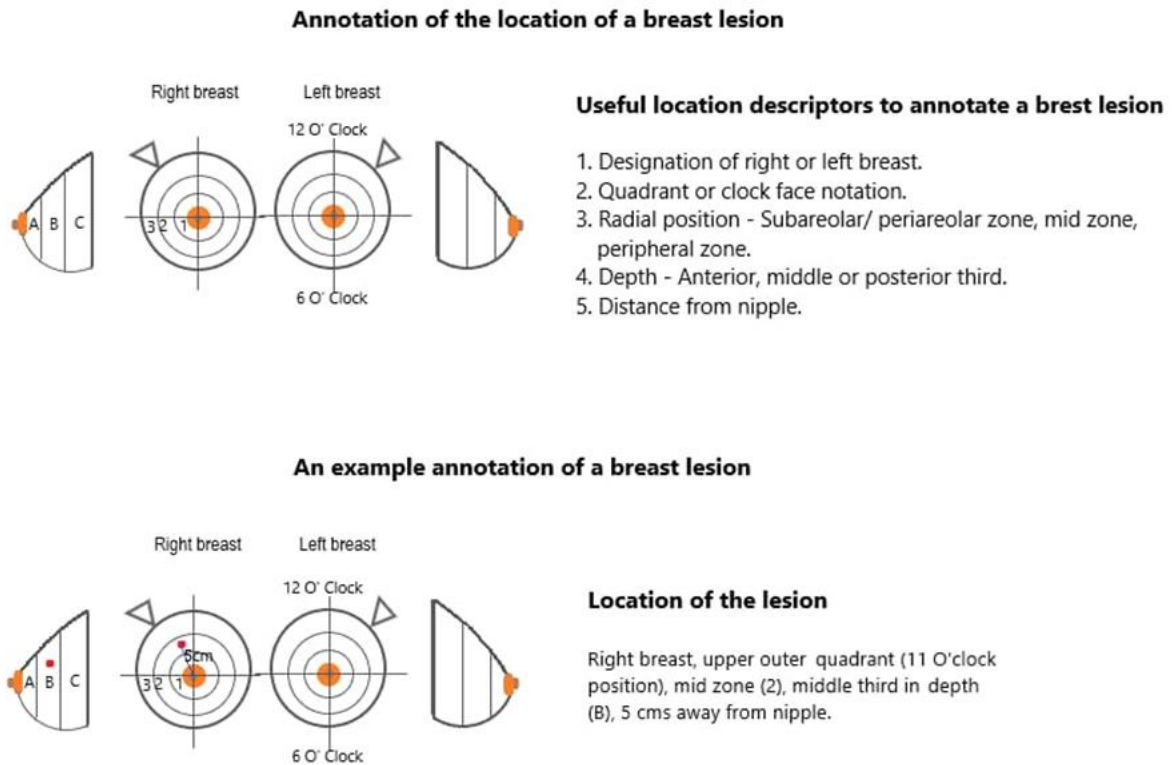
---

### 1.1 Introduction

The clinician plays a crucial role in optimizing the reporting of breast specimens. It is of utmost importance that the clinician provides adequate clinical and radiological details and ensures proper handling of the specimen in the theatre, during transport and until it is received by the laboratory. Adequate specimen fixation is especially important in breast specimens to ensure accurate assessment of prognostic and predictive biomarkers which will guide patient management.

### 1.2 General guidelines

- All specimens should be accompanied by a requisition form with adequate clinical and radiological details (site, size and nature of lesion and details of any previous biopsy or neoadjuvant therapy) (Annexure I).
- The requisition form should include a diagram indicating the location of the tumour in the breast (Figure 1.1) and the margin nearest to the nipple in excision specimens and identifying smaller tumours in mastectomy specimens. This is especially important in post- neoadjuvant therapy specimens, where identification of the tumour bed may be difficult.
- The recommended gauges of the needle used to obtain core biopsies are 14G to 16G.
- All excision / resection specimens should be oriented, placed immediately in formalin fixative as described below (section 2.4) and transported promptly to the laboratory.
- Sentinel nodes may be sent fresh for intraoperative diagnosis or in fixative for routine histological examination. Each pathology laboratory, in consultation with the surgical team, should determine which method is appropriate for them depending on the resources and expertise available in the local setting.



**Figure 1.1** Diagram to indicate the exact location of the tumour within the breast

### 1.3 Specimen orientation [X]

- Surgeons are encouraged to establish a local protocol of orientation for all breast cancer excision specimens. e.g., **L**ong stitch - **L**ateral margin, **S**hort stitch - **S**uperior margin, **D**ouble stitches - **D**eep surface, **N**ylon - **N**ipple extension margin.
- If specimen demarcation differs from the agreed local protocol, this should be clearly stated on the requisition form.
- If no skin is present to indicate the superficial aspect of the specimen, three margins need to be identified by the surgeon to enable pathological orientation. The nipple extension margin/direction of the nipple should be separately marked.
- If more than one piece of tissue is removed, the relationship of the pieces should be made clear, to assist in determining the size of the lesion and distance to excision margins. (e.g., when the excision specimen is accompanied by an immediate re-excision).
- The surgeon should establish a local protocol for indicating the new excision margin of cavity shave specimens. This can be indicated by marking one of the surfaces using marker suture / staples. The pathologist can ink the new excision margin, taking care not to ink the internal margin, when handling the specimen.

- In post- neoadjuvant specimens, in addition to providing a detailed description of the exact pre-treatment tumour location (Figure 1.1), sutures/clips are to be placed by the surgeon to help in identifying residual tumour or tumour bed in specimens without radiologically or macroscopically identifiable lesions after therapy.

## 1.4 Specimen fixation [X]

- Specimens should be sent to the laboratory in a fixative, with the exception of specimens requiring intraoperative assessment (Frozen section). The recommended fixative for breast specimens is 10% neutral buffered formalin. Use of the appropriate fixative is especially important in breast specimens which often undergo further immunohistochemical and molecular testing. 10% neutral buffered formalin is the fixative recommended by the current ASCO/CAP guidelines for breast specimens being tested for oestrogen receptor (ER), progesterone receptor (PR) and HER2. However, buffered formalin fixatives are not widely available in histopathology laboratories in the Sri Lanka and 10% formal saline is used as an alternative. It is recommended that all relevant stakeholders work expeditiously towards ensuring the availability of 10% neutral buffered formalin, which is the recommended fixative in all laboratories in the country.
- When feasible communicate with the laboratory prior to sending specimens that would require slicing for optimizing fixation. These should be sent to the laboratory within 1 hour of specimen harvest.
- For mastectomy specimens if there is an **anticipated delay**, it is recommended to **discuss with the pathologist** and consider **one of the following options** to ensure adequate fixation, which is crucial for accurate histological assessment and assessment of prognostic and predictive biomarkers by immunohistochemical studies.
  1. Using a sharp knife (not a scalpel) carefully place a single clean sagittal cut across the tumour starting from the deep margin (posterior aspect) and ending below the skin, to facilitate fixation of tumour. Special precautions should be taken to ensure that the specimen is not separated into two.
  2. Inject formalin fixative into the tumour using a needle and syringe.
  3. Palpate the tumour and place a nick through the skin that is deep enough to pierce the tumour. Place a gauze wick through the nick extending into the tumour to ensure sufficient formalin penetration of the tumour.
- The specimen should be fixed immediately in a wide mouthed, leak proof container with an adequate volume (ideally ten times that of the specimen) of the recommended fixative. For large specimens where it may not be practical to have ten times the volume of fixative, it is necessary to ensure that there is

at least adequate fixative to submerge the specimen completely. It is recommended to place a gauze towel over the specimen to facilitate fixation and prevent specimen drying, especially for large specimens.

- The time of specimen harvest and the time of transferring the specimen to the fixative (cold ischemia time) should be documented in the requisition form.

### **Benefits of rapid fixation**

- Accurate histological grading
- Preservation of biomarkers for immunohistochemical detection of ER, PR, and HER2 and in situ hybridization (ISH) assessment of HER2 amplification status
- Accurate assessment of lymphovascular invasion and in situ component

### **Fixation requirements for breast cancer specimens**

- A minimum fixation time of 6 hours for core biopsies and 24 hours for excision specimens is essential. The maximum fixation time is 72 hours for both core biopsies and excision specimens. (Both under and over fixation affect the assessment of biomarker status and HER2 amplification status).
- Immediate fixation in 10% neutral buffered formalin is recommended.

*It is recognized that in local settings some institutions may not have been optimized to achieve the above objectives. All relevant stakeholders should work towards achieving these objectives at local level.*

A sample requisition form (Annexure I) and check list (Annexure II) have been included as annexures.

## **1.5 Special situations**

### **▪ Sentinel lymph node biopsy**

The surgeon should indicate the procedure used for sentinel node identification in the requisition form (e.g, dye vs radioisotope scan)

### **▪ Frozen section for sentinel lymph node biopsy**

The surgeon will need to discuss with the pathologist to determine if intra operative frozen section is appropriate depending on the resources and expertise available in the laboratory. The surgical team should inform the

pathologist in advance (preferably 24 hours prior) to ensure immediate handling of the frozen section sample on receipt to the laboratory.

- **Wire guided specimens**

It is advised to keep the guide wire in situ and to indicate the direction of the wire entering to the specimen.

## References

1. Allison KH, M. Hammond MEH, Dowsett M et al. Estrogen and Progesterone Receptor Testing in Breast Cancer: ASCO/CAP Guideline Update. *J Clin Oncol* 2020;38:1346-1366. DOI: 10.1200/JCO.19.02309. PMID: 31928404
2. Ellis IO, Carder P, Hales S et al. Pathology reporting of breast disease in surgical excision specimens incorporating the dataset for histological reporting of breast cancer. Royal College of Pathologists, 2016. Available at : [https://www.rcpath.org/uploads/assets/7763be1c-d330-40e8-95d08f955752792a/G148\\_BreastDataset-hires-Jun16.pdf](https://www.rcpath.org/uploads/assets/7763be1c-d330-40e8-95d08f955752792a/G148_BreastDataset-hires-Jun16.pdf)
3. Wolff AC, Hammond MEH, Allison KH et al. Human Epidermal Growth Factor Receptor 2 Testing in Breast Cancer American Society of Clinical Oncology / College of American Pathologists Clinical Practice Guideline Focused Update. *Arch Pathol Lab Med* 2018;142: 1364-1382. DOI: 10.5858 /arpa.2018-0902-SA. PMID: 29846104



## CHAPTER 2

# Handling and reporting of core needle biopsy and vacuum assisted biopsy specimens

---

### 2.1 Introduction

Core needle biopsy (CNB) and vacuum assisted biopsy (VAB) are used in the 'triple assessment' of breast disease of both screen detected and palpable lesions. In most cases they result in a definitive diagnosis, whereas in other cases correlation with radiological and clinical findings will help to devise a management plan. The core biopsy is also the preferred specimen for assessment of hormone receptors (ER, PR) and HER2 by immunohistochemistry (IHC).

### 2.2 Specimen handling [X]

#### Specimen collection and transport

- Proper interpretation of biopsies requires details of clinical history and radiological information (e.g., BI-RADS score, mass lesion, calcification, architectural distortion etc.) which should be provided on the requisition form.
- Biopsies should be placed immediately in formalin fixative and sent promptly to the laboratory.
- A minimum of 6 hours and a maximum of 72 hours is recommended for fixation.
- In the macroscopic description:
  - Record the number of containers with the number of cores in each
  - Measure the length of each core separately
  - Perform specimen radiography [Z]

### 2.3 Block selection

It is advisable to place each core in a separate cassette. [X]

## 2.4 Microscopy and conclusion [X]

- Confirm that the length corresponds to the macroscopic measurement. One level is usually sufficient for core biopsies from mass lesions, but core biopsies taken for the investigation of microcalcification should have a minimum of three levels examined.
- More levels may be required depending on the clinical context e.g., if initial sections do not show calcification in a core biopsy taken for microcalcification.
- Ensure preservation of sufficient material in the paraffin block for further levels and immunohistochemistry to be performed.
- If the core biopsy is negative in a lesion that is clinically or radiologically suspicious for a malignancy, mention the number of levels examined.

## 2.5 Diagnostic categories [Y]

- **B1 – Normal breast tissue:** A core of normal tissue. This category is appropriate for normal breast tissue or other normal tissue, including adipose tissue. Lactational change, minor degrees of fibrocystic change, specimens with excessive crush artefact or blood clot only should also be categorised as B1.
- **B2 – Benign:** A core is containing a benign abnormality. This includes fibroadenoma, fat necrosis, fibrocystic change, usual ductal hyperplasia, sclerosing adenosis, abscess and duct ectasia.
- **B3 – Lesion of uncertain malignant potential:** Lesions that may provide a benign histology but are known to show heterogeneity or have an increased risk of associated malignancy. This includes atypical ductal hyperplasia, lobular neoplasia (atypical lobular hyperplasia and lobular carcinoma in situ - LCIS), fibroepithelial lesions with cellular stroma, phyllodes tumours, papillary lesions (with a few exceptions), flat epithelial atypia, mucocele-like lesions and radial scar.
- **B4 - Suspicious of malignancy:** A definite malignant diagnosis (ductal carcinoma in situ-DCIS or invasive carcinoma) is not possible because of crush artefact, poor fixation, or a small focus of suspicious but non-diagnostic cells. This category also includes non-high grade intra ductal proliferation with a significant degree of atypia probably representing intermediate or low-grade DCIS that involves only a few duct spaces, lesions that are difficult to classify as LCIS or DCIS, and non-pleomorphic LCIS with necrosis.  
**Note:** Definitive therapeutic surgery should not be undertaken for a B3 or B4 core biopsy diagnosis. Hence either diagnostic excision biopsy or repeat core biopsy sampling for B3 and B4 categories should be suggested.
- **B5 – Malignant:** An unequivocal malignant diagnosis.

Unequivocal DCIS of all grades (Including Paget's disease of the nipple)	B5a
Pleomorphic LCIS	B5a
Malignant papillary lesion	B5a
Invasive breast carcinoma	B5b
Other malignancies (e.g., lymphoma, malignant phyllodes, metastatic tumours)	B5b
Cases where it is not possible to say whether the carcinoma is invasive or in situ	B5c
e.g., large fragments of carcinoma with no surrounding stroma	
Unequivocal DCIS and features suspicious of invasion, but not sufficient for a definite diagnosis of invasive carcinoma	

### **The pathology report of DCIS in a CNB should include:**

- Nuclear grade (low, intermediate, or high)
- Architectural type(s)
- Presence of necrosis (comedo or punctate type)
- Presence of microcalcification, particularly if the biopsy was for the investigation of calcification, in order to correlate with the imaging finding

### **The pathology report of invasive carcinoma in a CNB should include:**

- Histological type
- Provisional grading (Note: If the biopsy does not contain an adequate number of microscopic fields to assess the mitotic count, state the mitotic count per available number of fields with the field diameter/field area)
- Presence of lymphovascular invasion
- Presence or absence of DCIS/ Pleomorphic LCIS
- Tumour infiltrating lymphocytes (TILs) **[Y]**
- ER, PR, HER2 and Ki 67 status
- Surrogate molecular subtype by IHC

**Note:** The grade on core biopsy may differ from the excision specimen (usually by only one level). In particular, mitotic count may be lower in the core biopsy than in the excision specimen, leading to underestimation of grade on the core. Clinicians should be informed that the grade may differ from that in the subsequent resection specimen. A phrase such as 'Provisional (core) grade' can be used.

## References

1. Bilious, M. Breast core needle biopsy: issues and controversies. *Mod Pathol* 2010; 23, S36–S45. <https://doi.org/10.1038/modpathol.2010.34> PMID: 20436501
2. Ellis IO, Humphreys S, Michell M, et al. Best Practice No 179. Guidelines for breast needle core biopsy handling and reporting in breast screening assessment. *J Clin Pathol* 2004;57:897–90. DOI: 10.1136/jcp.2003.010983 PMID: 15333647
3. Lee AH, Carder P, Deb R et al. Guidelines for non-operative diagnostic procedures and reporting in breast cancer screening. London, England: The Royal College of Pathologists, 2016. Available at : <https://www.rcpath.org/uploads/assets/4b16f19c-f7bd-456c-b212f557f8040f66/G150-Non-op-reporting-breast-cancer-screening-Feb17.pdf>

## CHAPTER 3

# Handling and reporting of excision and mastectomy specimens

---

### 3.1 Introduction

Mastectomy and excision specimens of the breast are handled frequently by all histopathology laboratories. Excision specimens include both therapeutic and diagnostic specimens. Proper handling of the specimens in the laboratory is crucial for an accurate diagnosis and determination of all prognostic variables that are important for patient management.

### 3.2 Types of specimens

#### 3.2.1 Types of excision specimens

##### A. Therapeutic (Therapeutic wide local excisions)

- Wide local excisions for invasive carcinoma (including oncoplastic wide local excisions): presenting as a mass lesion.
- Wide local excisions for in situ carcinoma (DCIS and pleomorphic lobular carcinoma in situ): presenting as mammographic calcification.
- Cavity shave/bed biopsy specimens.
- Re-excision specimens.

##### B. Diagnostic (Diagnostic localization excisions)

#### 3.2.2 Types of mastectomy specimens

- A. Total mastectomy:** Removal of all breast tissue generally including nipple and areola.
- B. Simple mastectomy:** Total mastectomy without removal of axillary fat.
- C. Nipple sparing mastectomy:** Total mastectomy without removal of nipple.
- D. Skin sparing mastectomy:** Total mastectomy with removal of nipple and surrounding narrow rim of skin.
- E. Modified radical mastectomy:** Total mastectomy with axillary dissection. A small portion of pectoralis muscle can be included.
- F. Radical mastectomy:** Removal of total breast including pectoralis major and pectoralis minor muscles and axillary contents.

### 3.3 Wide local excisions for invasive carcinoma: presenting as a mass lesion

#### 3.3.1 Specimen handling [X]

##### ▪ Specimen orientation

- Should be done according to the details given in the requisition form.
- Nipple extension margin should be separately identified.
- In wire guided wide local excisions, identify the direction of the guide wire entering into the specimen according to the information provided on the requisition form.

##### ▪ Differential inking

- Should be done according to a protocol (If it differs from the local protocol margins should be identified according to the colours used).
- It is advised to dip/wipe the specimen in absolute alcohol (to remove surface fat) and allow to dry and then apply an appropriate colouring agent such as India ink. India ink can be fixed to the specimen using 10% acetic acid.

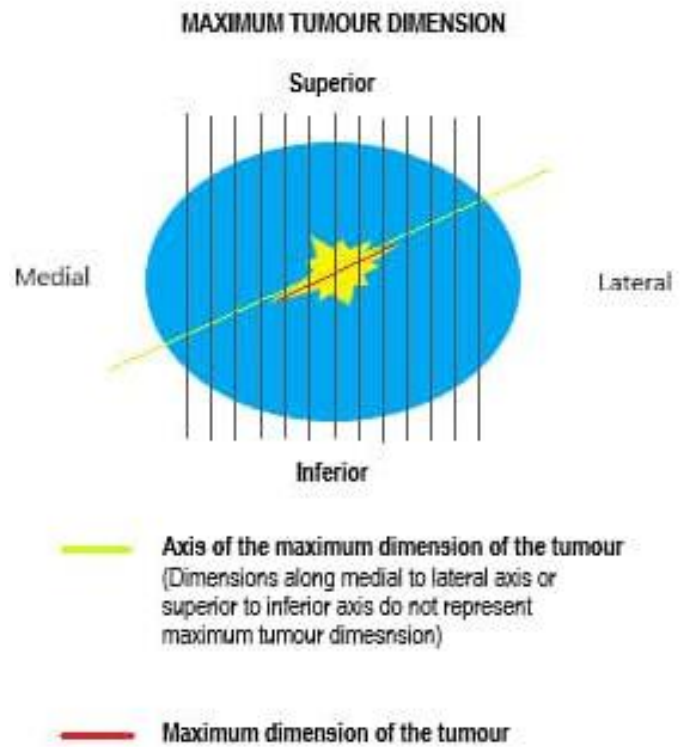
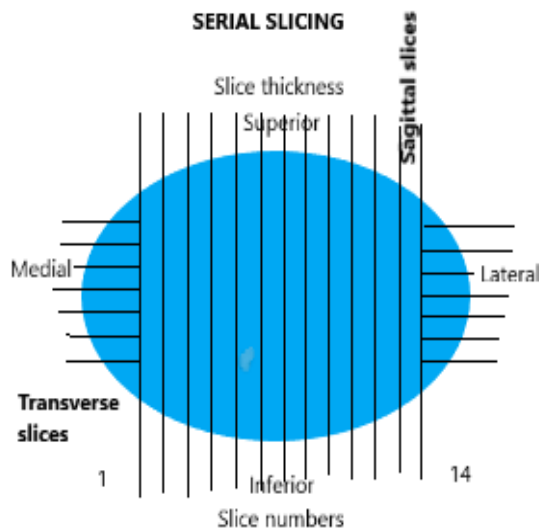
##### ▪ Specimen measurements

- All measurements should be taken in mm.
- Three dimensional measurements should be taken.
  - Superior to inferior
  - Medial to lateral
  - Superficial (anterior) to deep (posterior)

##### ▪ Slicing of specimen:

- Cold ischemia time (time from specimen excision to initiation of fixation) should not exceed more than one hour.
- Some WLE specimens are small and would not require slicing on receipt to the laboratory. These can be fixed overnight and sampled the next day. However, in the case of large WLE specimens, it is recommended to serially slice the specimen at 10mm intervals on receipt to the laboratory. Slices should not be completely separated. They are kept apart creating a gap between the slices using an appropriate absorbent material.
- The specimen should be serially sliced at intervals of approximately 3–5 mm, perpendicular to the long axis of the specimen when sampling (Figure 3.1).
- Extra caution needs to be taken to keep the margins and the tumour uninterrupted when handling a wire guided specimen.

- **Macroscopic tumour extent** (describe) - Localized vs multiple tumours.
- **Macroscopic tumour size**
  - This should be measured in three dimensions in millimetres. Special attention should be paid to take the maximum dimension (Figure 3.2).



**Figure 3.1** Serial slicing of an excision specimen

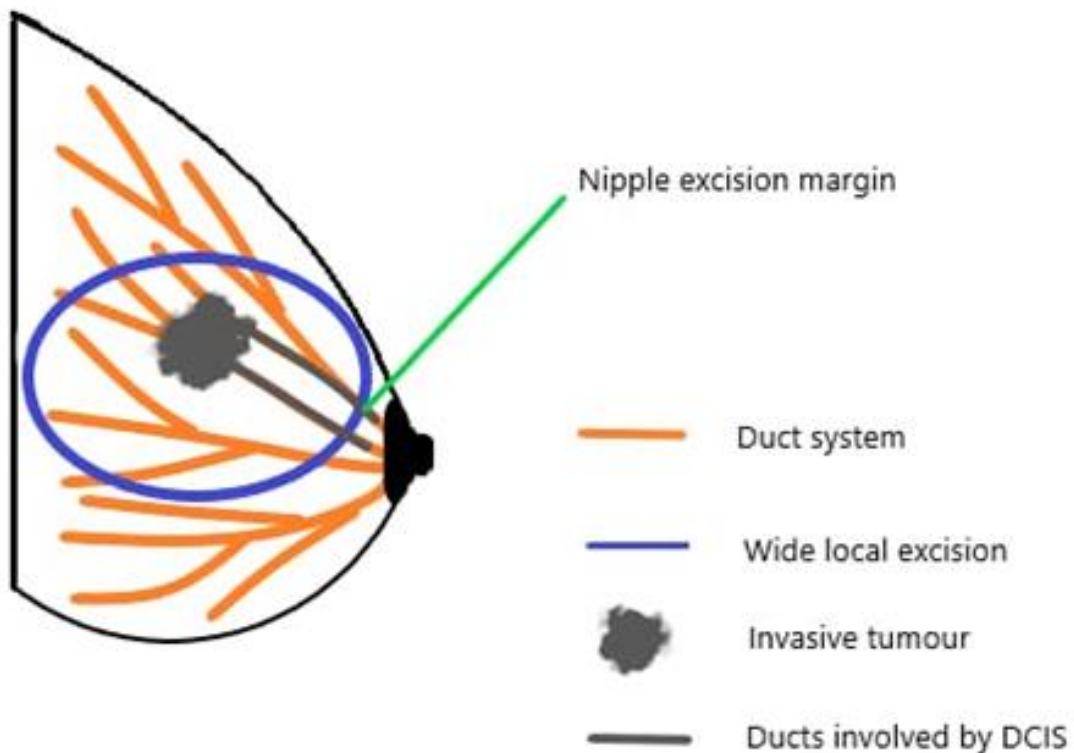
**Figure 3.2** The maximum dimension of the tumour is along the axis marked in red

### 3.3.2 Block selection [X]

- Sampling should allow accurate microscopic assessment of the invasive tumour size, whole tumour size (both invasive and in situ components; DCIS or pleomorphic LCIS, if present) and distance to margins including the nipple excision margin
- Blocks should be taken from the intervening tissue if there are more than one tumour.
- In wide local excision specimens, the nipple extension margin can get involved by DCIS and therefore accurate identification of the margin and adequate sampling of the shaved margin is recommended (Figure 3.3).
- The tumour edge with surrounding uninvolved tissue should be examined microscopically in all three dimensions to identify associated DCIS and peritumoral lymphovascular invasion not visible to the naked eye.

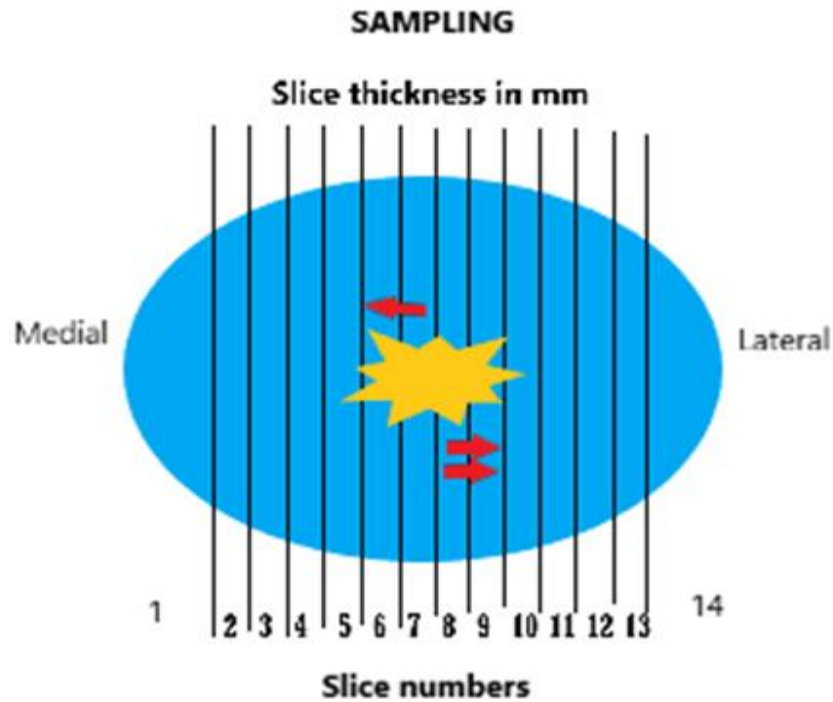
- The number of blocks to be taken is dependent on the size of the tumour. Figures 3.4, 3.5 and 3.6 demonstrate how to sample the tumour in order to accurately determine the size.
- Macrophotography or diagrams are advisable to assist in recording macroscopic findings.
- A block map and detailed block description will facilitate accurate microscopic assessment of the size of the tumour and distance to margins.

### Ramifying nature of duct system and nipple excision margin in wide local excision specimens



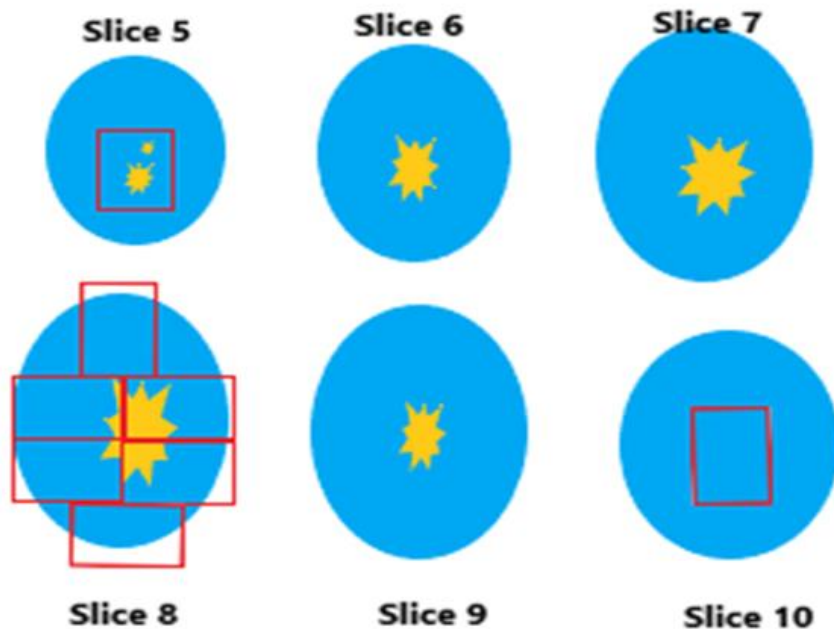
**Figure 3.3** Nipple extension / excision margin



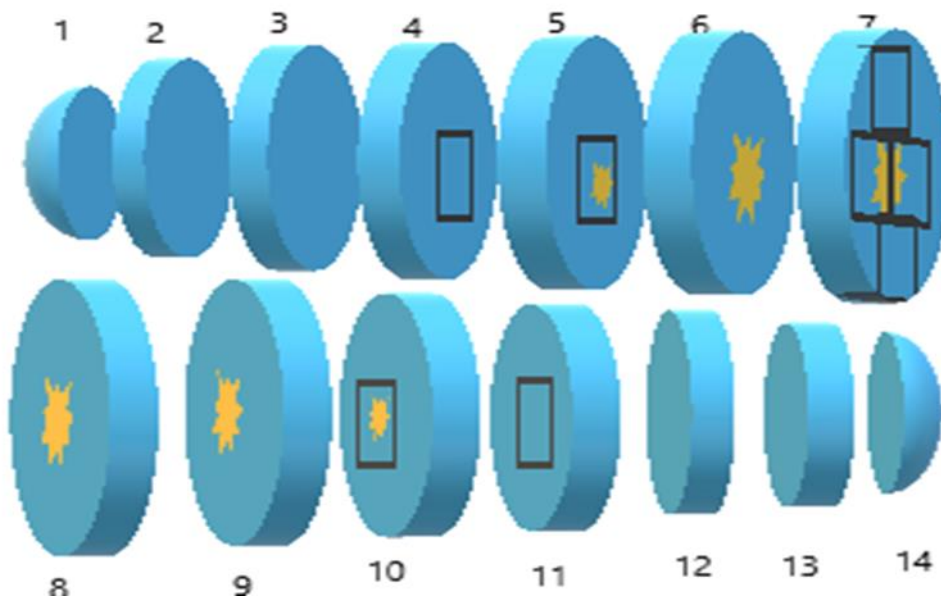


**Figure 3.4** Macroscopic tumour involves slice number 5 lateral face (single arrow) to slice number 10 medial face (double arrows). It is required to record thickness of the slices to assess the long axis dimension

**VIEW OF LATERAL FACES OF SLICES AND BLOCKS TAKEN**



**Figure 3.5** View of lateral faces of the slices with tumour as shown in figure 4.4.



**Figure 3.6** Three-dimensional view of slices to show how composite and consecutive blocks can be used to assess the size of the tumour. Slices are numbered from medial to lateral. Slice numbers 1-7 show lateral faces. Slice numbers 8-14 show medial faces. Composite blocks from lateral face of slice number 7 are to assess superior to inferior and anterior to posterior dimensions. Consecutive blocks from slice numbers 4 and 5 are to assess medial boundary of the tumour. Consecutive blocks from slice numbers 10 and 11 are to assess the lateral boundary of the tumour. Edges of the tumour with surrounding uninvolved tissue are taken in all three dimensions to assess the invasive tumour size, whole tumour size and peritumoral lymphovascular invasion.

## 3.4 Mastectomy

### 3.4.1 Specimen handling [X]

In addition to the details described above in 4.3.1 for wide local excision specimens, the following details should be assessed in mastectomy specimens.

- **Specimen measurements**

- When axillary tissue attached to the mastectomy is present, it should be measured separately.
- Measure the specimen size in three dimensions with measurements along medial-lateral, anterior-posterior (superficial-deep) and superior-inferior axis.

### ▪ **External appearance**

Record the following:

- The presence of skin/ nipple in the specimen
- If skin is present, the dimensions of the skin
- The presence of any skin/nipple abnormalities, including:
  - Ulceration / excoriation
  - Oedema including peau d'orange appearance
  - Satellite skin nodules
  - Surgical scars
  - Nipple retraction
- The presence of deep muscle attached to the specimen
- Details of lymph nodes (As described in chapter 5)

### ▪ **Inking of specimen**

Relevant surgical margins should be inked

e.g., Deep / posterior margin

Position of nipple (in nipple sparing specimens)

Any other margin close to tumour (e.g., superior, inferior)

### ▪ **Slicing of specimen**

- Serially slice the breast with a long sharp knife in parallel slices perpendicular to medial to lateral axis, starting from the deep/posterior surface.
- Slices should remain attached together by skin. Place the sliced specimen in the formalin container with gauze towels / paper towels in between the slices for further fixation.
- Allow the the specimen to fix for 24 hours (not more than 72 hours).
- Specimens received fresh may be allowed to cool in the freezing compartment of a refrigerator for up to 20 minutes to facilitate specimen slicing.

### ▪ **Macroscopy of the tumour**

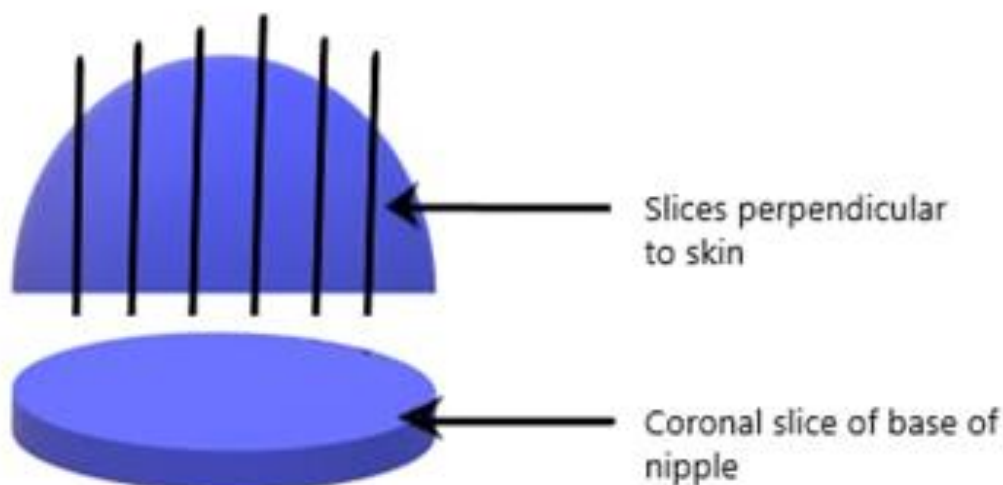
- Locate the quadrant/s of the lesion / lesions and correlate with radiological findings when available and describe the macroscopic tumour extent – localized vs multiple tumours.
- Specimen radiographs would be helpful in assessing the plane of maximum dimension.
- Measure the size (in three dimensions) of the lesion/s in mm and describe the cut surface for the presence of necrosis, cystic change and haemorrhage.

- When there are multiple tumours macroscopically, measure the macroscopic distance between each tumour.
- Measuring distance to margins: Measure the distance from the lesion/s to the skin, deep surgical margin, nipple, and any other relevant surgical margins.

### 3.4.2 Block selection [X]

- Block selection should be done for accurate assessment of invasive and whole tumour sizes and extent (localised vs multiple tumours) as explained in 4.3.2.
- Blocks should be taken from the intervening tissue if there is more than one tumour.
- Sampling nipple – Submit one block from the base of the nipple and representative block/s of the nipple or macroscopically visible lesions taken perpendicular to the skin surface (Figure 3.7).
- Sample any nodules or abnormal areas in the skin.
- Sample any other abnormalities in the background breast.
- Sample the margins of a mastectomy specimen, if the tumour is very close to or abutting a margin; this includes the anterior margin of skin-sparing mastectomies.
- The block key should be included in the report.

#### How to sample nipple



**Figure 3.7** Sampling of the nipple

### **Blocks to be taken from mastectomy and therapeutic wide local excision specimens:**

- At least three blocks of tumour (3-5 blocks)
- Blocks from tissue adjacent to the tumour to facilitate accurate measurement of the maximum dimension of the invasive and whole tumour and identification of DCIS and lymphovascular invasion
- Representative sections to include the closest inked margins
- If more than one tumour is present - blocks of intervening tissue
- Any other suspicious areas
- Background breast tissue (ensure sampling of fibrous rather than fatty tissue)
- Nipple and any abnormal areas of the skin in a mastectomy specimen

## **3.5 Microscopy and conclusion for therapeutic wide local excision and mastectomy [X]**

### **Tumour type and extent:**



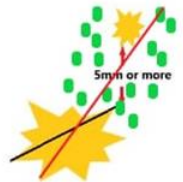





#### **Tumour type**

- Tumours are typed according to the WHO Classification of Epithelial Tumours of the Breast, 5<sup>th</sup> edition (currently in use in 2021) - Annexure III.
- If there are multiple invasive tumours of different histological types, mention them separately. An invasive breast carcinoma of no special type (IBC – NST) associated with 10-90% of a special subtype is classified as a ‘mixed IBC-NST and special subtype carcinoma’. The percentage of the special type of breast carcinoma should be mentioned. The grade and biomarker status of both components should be reported because they can be distinct.
- Cancers with < 10% of a special subtype should be classified as IBC-NST, with the focal specialized subtype optionally described in the report
- Cancers with >90% of a specialized subtype should be classified as the special subtype

---

**Tumour extent  
(localized vs. multiple  
tumours)**

- Tumour extent has important implications for treatment planning. Accurate assessment is expected.
- Tumours can have multiple invasive foci which are connected with associated DCIS. These tumours should be designated as localized tumours with multiple invasive foci (scenarios 3 and 6 of figure 3.7).
- When there is a separate invasive focus within the specimen, clearly separated from the main invasive tumour by 5mm or more and not connected by associated DCIS, this should be considered as multiple tumours (scenario 5 of figure 3.7). If a separate focus of tumour is 5 mm or more away from the first tumour, the chances of the deposits representing one tumour appearing as separate focus due to plane of slicing is low. Therefore, such focus should be considered as a separate tumour if the intervening tissue is free of DCIS.
- Tumour with multiple areas of invasion within extensive DCIS should not be classified as multiple tumours (scenario 6 of figure 3.7).
- Multiple synchronous primary tumours of different types should also be categorised as multiple.

<p><b>Scenario 1 - Localized tumour</b> Invasive tumour with no DCIS extending beyond the confines of invasive tumour</p>	
<p><b>Scenario 2 - Localized tumour</b> Invasive tumour with DCIS extending beyond the confines of invasive tumour</p>	
<p><b>Scenario 3 - Localized tumour</b> Separate focus of invasive tumour connected by DCIS</p>	
<p><b>Scenario 4 - Localized tumour</b> Separate focus of invasive tumour is less than 5mm from the other focus of invasive tumour Separate focus is included in the invasive tumour size</p>	
<p><b>Scenario 5 - Multiple tumours</b> Separate invasive tumours which are 5mm or more apart from each other and separated by normal intervening breast tissue (not connected by DCIS) Separate tumour is not included in the invasive tumour size</p>	
<p><b>Scenario 6 - Localized tumour</b> Multiple invasive foci connected by DCIS</p>	
<p><b>How to determine localized tumour vs multiple tumour and how to measure invasive and whole tumour sizes</b></p> <p>  Invasive tumour      — Invasive tumour size   DCIS                      — Whole tumour size </p>	

**Figure 3.7** Demonstration of how to measure the invasive tumour size and whole tumour size in different scenarios, and how to determine localized tumour vs. multiple tumours. Scenario 5 shows a separate invasive tumour which is more than 5mm apart from the larger invasive tumour by normal intervening breast tissue (not connected by DCIS). Therefore, scenario 5 indicates multiple tumours. Scenarios 3 and 6 show more than one invasive focus, connected by intervening DCIS and hence indicate localized tumour.

<b>Tumour grade</b>	Nottingham grade 1 / 2 / 3 (Annexure IV) <ul style="list-style-type: none"><li>▪ Determine the grade in all histological tumour types.</li><li>▪ In a case with multiple invasive carcinomas, grade each tumour separately.</li><li>▪ Do not grade microinvasive carcinomas.</li></ul>
<b>Tumour size:</b>	Invasive tumour size and whole tumour size should be determined.
<b>Invasive tumour size</b>	<ul style="list-style-type: none"><li>▪ The microscopically verified maximum dimension of the invasive tumour is used for pathological T stage.</li><li>▪ For circumscribed tumours the macroscopic measurement may be accurate, if measured to the nearest millimetre. (The circumscription should be verified microscopically).</li><li>▪ For diffuse tumours it may be problematic to define the precise borders of the tumour macroscopically. Therefore, the maximum microscopic dimension should be taken.</li><li>▪ When accurate measurement is not feasible (e.g., when the specimen is sent in separate pieces without orientation) it should be clearly stated in the report. In such an instance the tumour size identified by imaging (ultrasound scan, mammogram, magnetic resonance imaging) should be used, as the best available record of true tumour size and should replace pathological size assessment.</li><li>▪ If more than one focus of invasion is present, the tumour size is determined by the size of the largest contiguous area of invasion. The size of multiple invasive carcinomas should not be added together. The size does not include adjacent ductal carcinoma in situ (DCIS). The exception to the size rule is, if two histologically similar carcinomas are present less than 5mm from each other. It is then considered as a single tumour and the tumour size is measured from outer edges of the two tumours (Figure 3.7).</li><li>▪ Two tumours that are 5mm or more apart from each other should be considered as separate tumours (Figure 3.7).</li></ul>



- Lymphovascular invasion should not be added to the measurement of the maximum invasive tumour dimension.
- Any carcinoma larger than 1.0 mm but less than 1.5 mm, size should be rounded up to 2.0 mm, to ensure that the tumour is not miscategorized as pT1mi.
- To determine the tumour size in a small invasive carcinoma (i.e.,  $\leq 10$  mm) with adjacent biopsy site changes
  - Compare the largest size on the previous core biopsy and the size of tumour in the excision specimen. The larger of the sizes is taken as the dimension for the T staging.
  - Do not add sizes of the core biopsy and the excision since this will generally overestimate the size of the carcinoma.
  - The same should be applied if the entire tumour has been removed by prior biopsy.

---

#### **Whole tumour size**

- Whole tumour size is used in treatment planning. Accurate size measurement is expected.
- Whole tumour is the largest dimension of the tumour including the invasive and in situ (DCIS or pleomorphic LCIS, but not classical lobular neoplasia) components.
- Lobular neoplasia of classical type is generally multifocal and measurement of the extent of this is unreliable.

---

#### **In situ component (DCIS and pleomorphic LCIS)**

- DCIS is a recognised predictive factor for local recurrence, which is used in treatment planning. The percentage of DCIS should be mentioned.
- Extensive intraductal carcinoma is defined by the following criteria:  
Invasive cancers that show both prominent DCIS within the confines of the invasive tumour (typically occupying at least 25% of the tumour) **and** DCIS in the adjacent breast tissue  
**OR**  
Lesions composed primarily of DCIS associated with one or more foci of invasive carcinoma.
- The in-situ component is reported as outlined below:

- **Ductal carcinoma in situ (DCIS):** Present/Absent  
When DCIS is present determine the following:
  1. Architectural pattern
    - Solid
    - Cribriform
    - Micropapillary
    - Paget disease (DCIS involving nipple skin)
    - Other (Specify)
  2. Nuclear grade (Annexure V)
    - Grade I (low)
    - Grade II (intermediate)
    - Grade III (high)
  3. Necrosis
    - Not identified
    - Present, focal (small foci or single cell necrosis)
    - Present, central (expansive “comedo” necrosis)
  4. Percentage of DCIS
- **Lobular neoplasia:** Present/Absent  
When present describe the type.

<b>Tumour extension</b>	<p>For mastectomy specimens and WLE specimens including a skin ellipse:</p> <ul style="list-style-type: none"> <li>▪ Record if skin is present or absent. When skin is included in the specimen determine the Following:           <ul style="list-style-type: none"> <li>○ Skin is present but not involved.</li> <li>○ Invasive carcinoma directly invades into the dermis or epidermis without skin ulceration.</li> <li>○ Invasive carcinoma directly invades into the dermis or epidermis with skin ulceration.</li> <li>○ There are satellite skin foci of invasive carcinoma.</li> </ul> </li> </ul>
-------------------------	---

**Note:** Macroscopically identifiable tumour nodules of the skin which are not contiguous with the underlying invasive carcinoma in the breast are assigned to the category of T4b. Microscopic foci of tumour in the skin, in the absence of epidermal ulceration or skin oedema, are not categorized as T4b.

- Nipple

Describe as follows:

- DCIS does not involve the nipple epidermis
- DCIS involves nipple epidermis (Paget disease of the nipple)

- Record if skeletal muscle is present or absent.

Identify pectoralis and deep muscles separately and comment as follows:

- Skeletal muscle is free of carcinoma
- Carcinoma invades skeletal muscle
- Carcinoma invades into skeletal muscle and into the chest wall.

---

### **Tumour infiltrating lymphocytes [Y]**

Pathologists are encouraged to report the percentage of stromal tumour infiltrating lymphocytes (Annexure VI).

---

### **Lymphovascular invasion**

- Lymphovascular invasion must be diagnosed outside the border of the invasive carcinoma. These foci are most often found within 1mm of the edge of the carcinoma.
- Lymphatics are often found adjacent to blood vessels and often partially encircle a blood vessel.
- Tumour emboli must be differentiated from retraction artefact. In contrast to retraction artefact, tumour emboli usually do not conform exactly to the contours of the space in which they are found.
- Endothelial cells should be seen lining the space.

Dermal lymphovascular invasion should be recorded for mastectomy specimens and WLE specimens with a skin ellipse.

---

### **Excision margins**

- The distance to the margins should be reported separately for the following components, rather than quoting 'complete' excision in histology reports.
  - Invasive carcinoma/s
  - Ductal carcinoma in situ
  - Pleomorphic lobular carcinoma in situ
- Margin status is taken as "positive" if there is ink on invasive carcinoma.
- In the case of DCIS, a margin of  $\geq 2\text{mm}$  is considered adequate clearance.

- Mention the distance in mm to the deep margin and any other close margins for each component in mastectomy specimens.
- Mention the distance in mm to all margins (including the nipple extension margin) in wide local excision specimens.
- Macroscopic measurement should be confirmed microscopically.

---

**Non neoplastic breast** Non neoplastic breast changes and any additional pathological findings

---

**Lymph node status** Refer chapters 5 and 6.

---

**Ancillary studies** Refer chapter 7.

- Hormone receptor status
- HER2 status
- Ki 67 proliferation index
- Basal markers where necessary.

---

**Surrogate molecular subtype by IHC [Y]** Refer chapter 7.

---

**Tumour stage (TNM)** TNM stage (pathologic stage classification pTNM, AJCC TNM 8<sup>th</sup> edition currently in use in 2021 - Annexure VII.

**Note:** Stage should be given according to the size of the largest invasive carcinoma e.g., solid papillary carcinoma with invasion and encapsulated papillary carcinoma with invasion are staged according to the size of the invasive component only. Solid papillary carcinoma in situ and encapsulated papillary carcinoma with no invasion are staged as Tis.

---

**Pathological prognostic stage group [Y]** This is determined according to the AJCC/TNM system (Annexure VII).

**Summary of items to be included in wide local excision and mastectomy reports:**

- Tumour type
- Tumour extent (localized vs. multiple tumours)
- Tumour grade
- Invasive tumour size
- Whole tumour size
- In-situ component (DCIS and pleomorphic LCIS)
- Tumour extension
- Tumour infiltrating lymphocytes [Y]
- Lymphovascular invasion
- Dermal lymphovascular invasion
- Excision margins
- Lymph node status
- Additional pathological findings e.g. microcalcification
- Results of ancillary studies
- Surrogate molecular subtype by IHC [Y]
- TNM stage
- Pathological prognostic stage group [Y]

### 3.6 Wide local excision for lesions presenting as mammographic calcification

#### 3.6.1 Specimen handling [X]

- Specimen orientation, differential inking, measurements, and slicing should be done as for wide local excision for invasive carcinoma, presenting as a mass lesion (4.3.1).
- The lesion may not be visible on macroscopic examination.
- If facilities are available, the specimen can be X-rayed after slicing to identify the areas of microcalcification. [Y]

#### 3.6.2 Block selection [X]

- Sampling should be adequate to determine the size of the lesion and excision margins accurately.
- If the specimen is small (e.g., < 30 mm), it is best to block and examine all the tissue.

- If the lesion is not visible macroscopically, sampling composite blocks and consecutive blocks of the whole abnormal area (fibrotic tissue) may be necessary.
- Macrophotography or diagrams are advisable to assist in recording macroscopic findings.
- A block map and a detailed block description will facilitate accurate microscopic assessment of the size of the tumour and distance to margins.

### 3.6.3 Microscopy and conclusion [X]

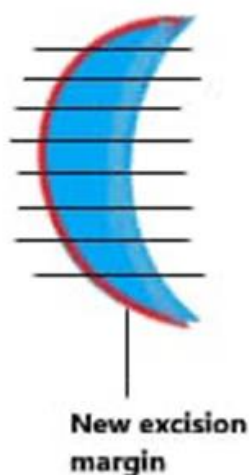
- If microcalcification is not identified, multiple levels must be examined till microcalcification is confirmed by microscopic examination.
- Accurate assessment of in situ component (DCIS and pleomorphic LCIS), invasive component (if present) and distance to excision margins is required.

## 3.7 Cavity shave / bed biopsy specimens

### 3.7.1 Specimen handling [X]

- Orientation of the specimen should be done according to the orientation sutures placed by the surgeon on new excision margin.
- Inking of the new excision margin should be done
- The specimen should be sliced perpendicular to the new margin face (Figure 3.8).

#### CAVITY SHAVE/BED BIOPSY SPECIMENS



**Figure 3.8** Slicing a cavity shave perpendicular to new excision margin.

### 3.7.2 Block selection [X]

- Cavity shaves should be sampled in total where feasible.
- For larger specimens requiring block selection, most suspicious areas should be sampled.

### 3.7.3 Microscopy and conclusion [X]

The size of the residual tumour should be identified and the distance to new margin should be recorded.

## 3.8 Re-excision specimens

### 3.8.1 Specimen handling [X]

- Re-excision specimen could be either immediate re-excision accompanied by a wide local excision (when radiological abnormality extends close to a margin /surgically palpable abnormality extending close to a margin) or could be after the discovery of incomplete excision in a therapeutic excision or following diagnostic localisation biopsy.
- Specimen orientation, differential inking, taking measurements, slicing, measuring the cavity size and residual lesion and measuring the distance to margins should be done as for wide local excision for invasive carcinoma, presenting as a mass lesion (section 3.3.1).

### 3.8.2 Block selection [X]

- Block selection should permit accurate assessment of the adequacy of excision and size of any residual tumour.
- Extent of block selection will depend on the nature and the size of the specimen.
- The focus should be on the new excision margin rather than exhaustive detection of residual disease.
- Prior knowledge of distance to margins / involved margins would be helpful in cases after therapeutic excision or diagnostic localisation biopsy.

### 3.8.3 Microscopy and conclusion [X]

The size of the residual tumour should be identified and the distance to the new margin should be recorded.

## 3.9 Diagnostic localization excision biopsies

### 3.9.1 Specimen handling [X]

- Diagnostic localisation excision biopsies are performed for lesions with indeterminate pre-operative diagnosis (e.g., C3 & C4 cytology and B3 & B4 core biopsies).
- Specimen orientation, differential inking, slicing, measuring macroscopic tumour size, measuring distance to margins and sampling should be done as for wide local excision for invasive carcinoma, presenting as a mass lesion (4.3.1).
- Localisation method, slice number with the tip of the guide wire and location of the tip in relation to macroscopic lesion, if present, should be recorded.
- Starting the serial slicing away from the guide wire is advisable to avoid the blade of the knife confronting with the guide wire.

### 3.9.2 Block selection [X]

- If the specimen is small (e.g., less than 30 mm), it is best to sample and examine all the tissue. Block selection is required for larger excisions.
- For poorly delineated tumours and DCIS, sampling composite blocks and consecutive blocks of the whole abnormal area (including adjacent fibrotic tissue) may be necessary.
- If no tumour is seen, extensive sampling would be necessary. A block map and a detailed block description will facilitate accurate microscopic assessment of the size of the tumour and distance to margins.
- Macrophotography or diagrams are advisable to assist in recording macroscopic findings.

### 3.9.3 Microscopy and conclusion [X]

If a tumour is detected, accurate assessment of invasive tumour size, whole tumour size, in situ component, tumour extent and status of excision margins are required (as for wide local excision for invasive carcinoma: presenting as a mass lesion) (section 3.5).

## References

1. Amin MB, Edge S, Greene F, Byrd DR, Brookland RK, Washington MK, Gershenwald JE, Compton CC, Hess KR, et al. (Eds.). AJCC Cancer Staging Manual (8<sup>th</sup> edition). Springer International Publishing: American Joint Commission on Cancer; 2017
2. College of American Pathologists. Protocol for the examination of resection specimens from patients with invasive carcinoma of the breast. February 2020. Available at: <https://documents.cap.org/protocols/cp-breast-invasive-resection-20-4400.pdf>
3. Ellis IO, Carder P, Hales S et al. Pathology reporting of breast disease in surgical excision specimens incorporating the dataset for histological reporting of breast cancer. Royal College of Pathologists, 2016. Available at [https://www.rcpath.org/uploads/assets/7763be1c-d330-40e8-5d08f955752792a/G148\\_BreastDataset-hires-Jun16.pdf](https://www.rcpath.org/uploads/assets/7763be1c-d330-40e8-5d08f955752792a/G148_BreastDataset-hires-Jun16.pdf)
4. Salgado R, Denkert C, Demaria S et al. The evaluation of tumour-infiltrating lymphocytes (TILs) in breast cancer: recommendations by an International TILs Working Group 2014. *Annals of Oncology* 26: 259–271, 2015. doi:10.1093/annonc/mdu450



5. The Royal College of Pathologists of Australia. Macroscopic cut-up manual: Breast tumour resection. Available at <https://www.rcpa.edu.au/Manuals/Macroscopic-Cut-Up-Manual/Breast/Breast-tumour-resection>.
6. WHO Classification of Tumours. Breast tumours. Lyon (France): International Agency for Research on Cancer; 2019. (WHO classification of tumours series, 5<sup>th</sup> ed.; vol. 2).

## CHAPTER 4

# Handling and reporting of therapeutic excision and mastectomy specimens after neoadjuvant chemotherapy

---

### 4.1 Introduction

Neoadjuvant treatment includes chemotherapy, endocrine therapy, and targeted therapy. It has represented a major shift in the management of breast cancer and is increasingly being used. Handling of surgical breast cancer specimens following neoadjuvant therapy has proven challenging, and pathologists must adopt a systematic approach to sort out troublesome sampling and reporting.

According to the AJCC (TNM 8<sup>th</sup> edition) staging classification, post treatment size of residual disease should be estimated based on the best combination of imaging, gross and microscopic findings. Complete clinical regression does not imply pathological complete response. Therefore, pathological assessment of the post neoadjuvant surgical resection specimen is still the gold standard for determining the complete response.

### 4.2 Specimen handling [X]

- The specimen received could be, an excision specimen or mastectomy with or without axillary lymph node dissection.
- The specimen of axillary lymph node dissection is handled the same way as for lymph nodes in the non-neoadjuvant setting (Chapter 5).
- The general handling of the excision or mastectomy specimen should be as described in chapter 3. Aspects specific to post neoadjuvant treatment specimens are outlined below.
- Obtain adequate clinical and radiological details including the following.
  - Size and exact location of the tumour before treatment (Figure 1.1).
  - Presentation of the lesion before treatment. (Palpable mass or radiologically detected lesion, skin changes, fixation to the chest wall etc.)
  - Prior diagnostic procedure (core biopsy/incisional biopsy) and the histological diagnosis. Information on the histological tumour type, preliminary tumour grade and biomarker status should be available.
  - Presence of a clip and /or calcifications in the tumour.
  - Prior evaluation of lymph nodes (e.g., FNA, core biopsy, sentinel node biopsy) and the results.

- The length of the chemotherapy, number of cycles given and time since last cycle.
- Tumour size and location after chemotherapy
- Details of clinical and radiological response (when available).
- Identification of the residual tumour or tumour bed is important in handling a specimen following neoadjuvant therapy. There are two patterns of tumour response:
  - Concentric shrinking
  - Scattered pattern
- The tumour bed appears as a poorly defined fibrotic area or simply fibrotic streaks and the residual tumour as fleshy nodules or areas.
- A detailed description of the exact pre-treatment tumour location (Figure 1.1) and sutures / clips placed by the surgeon will be helpful in identifying residual tumour or tumour bed in specimens without radiologically or macroscopically identifiable lesions after therapy.
- If the lesions are thought to be multiple, it is imperative to have the mammogram or at least a detailed radiology report describing the mammography data.
- In the local setting access to radiography facilities may be limited and metallic clips are not always placed in the tumour. Therefore, it would be helpful if there is a diagram clearly indicating the location of the tumour in the requisition form as described in chapter 1 (Figure 1.1) and annexure I.
- The overlying skin and nipple should be examined carefully to identify any skin changes.
- Examine the cut surface for evidence of tumour bed, residual tumour, and previous biopsy site especially at the locations corresponding to the radiology report.
- Measure the tumour bed (preferably in three dimensions). This is required for calculating the residual cancer burden index, even if there is little or no tumour remaining.
- Describe the tumour bed, giving the dimensions of any lesions suspicious for residual tumour within this area. The largest contiguous focus of such a lesion should be measured.
- Mention the quadrant of the tumour and the multifocality.
- Record the distance of the tumour bed to the closest surgical margin.
- Record the distance of any lesions suspicious of tumour to the closest surgical margin.
- A photograph of the slices of the breast tissue may be useful.

### 4.3 Block selection [X]

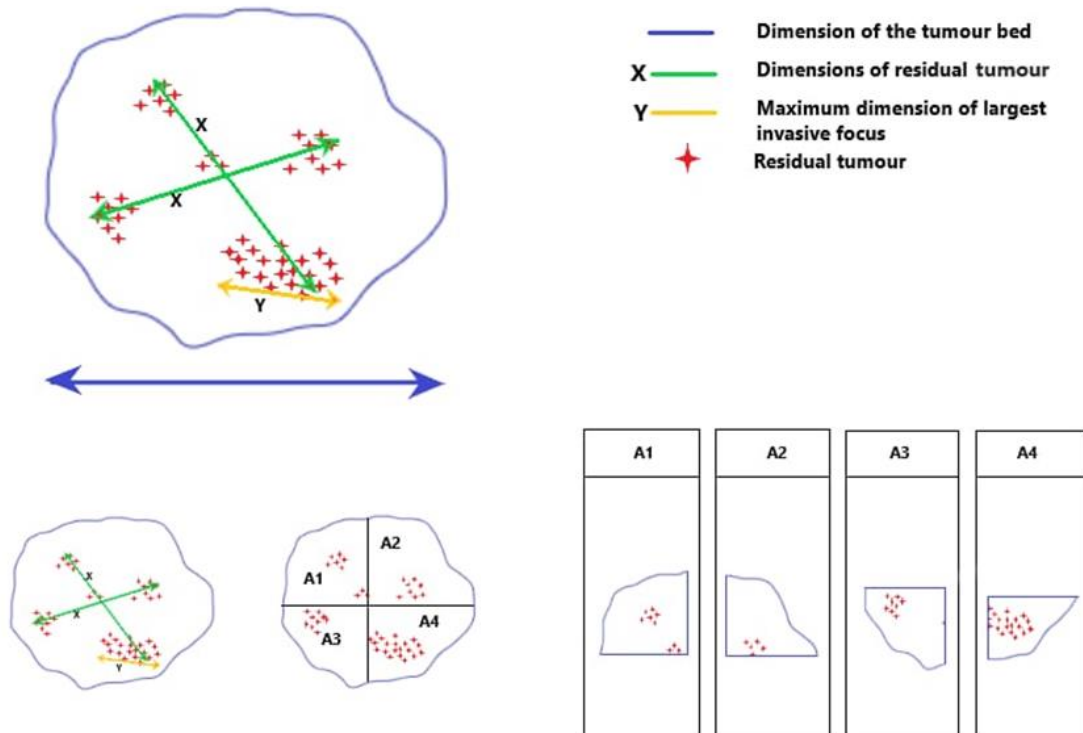
- For initial sampling take at least one block per 10mm of pre-treatment tumour size.
- If no tumour is found at this point, and the tumour bed is small (less than 50mm) embed the entire tumour bed.
- If the tumour bed is more than 50mm, block the largest cross-sectional area and specifically describe those blocks in the block key. Try to indicate how they are oriented.
- Describe any additional blocks taken from the surrounding tissues.
- Other blocks should be taken as described in Chapter 3, section 3.4.2.

### 4.4 Microscopy and conclusion [X]

- Determine whether there is pathological complete response or not.
- In some cases, it may be difficult to recognize the presence of residual cancer and to distinguish the tumour cells from histiocytes and fibroblasts in a sclerotic stroma. In such cases immunohistochemical staining with a pancytokeratin maybe useful. [Y]
- If residual tumour is present, the following information should be recorded.
  - Tumour type
  - Histological grade
  - The following dimensions must be determined:
    - Dimensions of the tumour bed (Figure 4.1 – blue arrows, measured in three dimensions)\*
    - Dimensions of residual tumour (Figure 4.1 - green arrows, measured in two dimensions)\*
    - Largest focus of invasive carcinoma (Figure 4.1 - yellow arrows)\*\*
    - Whole tumour size (in the presence of DCIS)
    - The macroscopic measurements should be confirmed microscopically (Figure 4.1)
    - If there is no residual tumour, mention the size of the tumour bed
  - \* These measurements are necessary for the calculation of the residual cancer burden (RCB).
  - \*\* This measurement is necessary for ypTNM staging.
- Multifocality
- Cellularity - residual tumour cellularity and change from pre-treatment cellularity (Annexure VIII)
- Percentage of tumour remaining in the tumour bed
- The steps in assessing the tumour bed are given in figure 4.1.

Submit composite blocks of the entire tumour bed area (if the tumour is < 50mm) or the largest cross-sectional area (if the tumour is > 50mm).

#### Measurements required in residual breast carcinoma following neoadjuvant therapy



**Figure 4.1** Steps in assessment of the primary tumour bed.

- Presence and extent of ductal carcinoma in situ.
  - Percentage
  - Type
- Lymphovascular invasion.
- Distance to relevant surgical margins with respect to tumour bed, invasive and in situ carcinoma.
- Other features – changes suggesting response to chemotherapy:
  - Fibrosis
  - Necrosis
  - Changes of nuclear morphology
  - Presence of calcifications
  - Changes in benign breast tissue
    - Significant atrophy of terminal duct lobular units
    - Reduction of the lobular acini
    - Attenuation of lobular ductal epithelium

- Lymph node status
  - Number of sentinel nodes
  - Number of total axillary nodes
  - Number of nodes with residual tumour and no histologic evidence of treatment response
  - Number of nodes with residual tumour and histological evidence of treatment response
  - Number of nodes with histological evidence of treatment response but no residual tumour
  - Size of the largest residual metastasis in lymph nodes
  - Extranodal extension
  
- Biomarkers (ER, PR, HER2, Ki-67) – Routine reassessment of biomarkers is not recommended for post neoadjuvant tumours. Reassessment of biomarkers can be considered in the following situations.
  - Negative or equivocal results on core biopsy
  - Insufficient invasive tumour on core biopsy
  - Heterogenous tumour in post chemotherapy specimen
  - Cases in which tumour does not demonstrate response to therapy
  - Request from oncologist
  
- Residual cancer burden **[M]** (Annexure VIII) or assessment of the tumour response to treatment by another method such as the system described below, which is a simple method to determine the tumour response and nodal response.
  - **Tumour response**
    - Complete pathological response, either
      - no residual carcinoma or
      - no residual invasive tumour but DCIS present.
    - Partial response to therapy, either
      - minimal residual disease/near total effect typically (e.g., <10% of tumour remaining in the tumour bed seen as an area of residual fibrosis delineating the original tumour extent) or
      - 10–50% of tumour remaining or
      - >50% of tumour remaining. (Comparison with the previous core biopsy sample may be helpful)
    - No evidence of response to therapy.
  - **Nodal response**
    - No evidence of metastatic disease and no evidence of changes in the lymph nodes.

- Metastatic tumour not detected but evidence of response/‘down-staging’, e.g., fibrosis.
  - Metastatic disease present but also evidence of response, such as nodal fibrosis
  - Metastatic disease present with no evidence of response to therapy.
- Post-treatment ypTNM/AJCC staging

**Summary of items to be included in reports from post neoadjuvant therapy specimens:**

- Presence of pathological complete response or not
- Size of tumour bed
- If there is residual tumour
  - Tumour type
  - Tumour grade
  - Invasive tumour size
  - Whole tumour size
  - Tumour extent (localized vs. multiple tumours)
  - Cellularity of residual tumour
  - Percentage of tumour remaining in the tumour bed
- In-situ component (DCIS and pleomorphic LCIS)
- Lymphovascular invasion
- Excision margins
- Lymph node status
- Additional pathological findings e.g. microcalcification, fibrosis, necrosis
- Results of ancillary studies
- Assessment of tumour and nodal response to therapy
- ypTNM stage

## References

1. Amin MB, Edge S, Greene F, Byrd DR, Brookland RK, Washington MK, Gershenwald JE, Compton CC, Hess KR, et al. (Eds.). AJCC Cancer Staging Manual (8<sup>th</sup> edition). Springer International Publishing: American Joint Commission on Cancer; 2017
2. Ellis IO, Carder P, Hales S et al. Pathology reporting of breast disease in surgical excision specimens incorporating the dataset for histological reporting of breast cancer. Royal College of Pathologists, 2016. Available at : [https://www.rcpath.org/uploads/assets/7763be1c-d330-40e8-95d08f955752792a/G148\\_BreastDataset-hires-Jun16.pdf](https://www.rcpath.org/uploads/assets/7763be1c-d330-40e8-95d08f955752792a/G148_BreastDataset-hires-Jun16.pdf)
3. Mrkonjic M, Berman HK, Done SJ, et al. Breast specimen handling and reporting in the post neoadjuvant setting: challenges and advances. *J Clin Pathol* 2019;72:120–132. doi: 10.1136/jclinpath-2018-205598. PMID: 30670564
4. Pinder SE, Provenzano E, Earl H, Ellis IO. Laboratory handling and histology reporting of breast specimens from patients who have received neoadjuvant chemotherapy. *Histopathology* 2007;50:409–417.
5. The University of Texas MD Anderson Cancer Center. Residual cancer burden calculator. Available at <http://www3.mdanderson.org/app/medcalc/index.cfm?pagename=jsconvert3>



## CHAPTER 5

# Handling and reporting of axillary clearance specimens

---

### 5.1 Introduction

Sentinel lymph node excisions and lymph node dissections are undertaken to assess the extent of regional nodal tumour metastases. The lymph nodes are sent either separated according to levels or en masse. The lymph node stage is an important prognostic factor that affects patient survival outcomes.

### 5.2 Specimen handling [X]

- All axillary lymph nodes should be dissected from the specimen.
- Lymph nodes are best identified in the axillary adipose tissue by combined palpation and inspection.
- Record the procedure as stated by the surgeon with the laterality. e.g., right axillary clearance.
- Orientation
  - Orientate and identify any anatomical features of the specimen. e.g., presence of skin, muscle tissue, blood vessels etc.
  - Record additional orientation or designation provided by operating surgeon, e.g., sutures, metal clips etc. to mark apex of the axillary clearance.
  - If the nodes have been divided into three levels by surgeon, this orientation should be identified and preserved.
- Specimen description
  - Measure the size of the specimen in three dimensions, in mm.
  - Specify the total number of nodes harvested. Most axillary dissections should yield between 10 to 20 lymph nodes. If fewer than 10 nodes are found grossly, re-examine the specimen and submit any area that may represent lymph nodes. Suspicious areas include palpable, brownish, firm tissue around vessels. Identification of fewer lymph nodes may lead to under staging.
  - The description should include the location of nodes according to a standard code e.g., axilla level I, axilla level II, axilla level III, internal mammary chain.
  - Mention the size of the largest macroscopic lymph node and/or tumour mass in the axillary tissue.

### 5.3 Block selection [X]

- All lymph nodes identified should be examined histologically.
- The apical lymph node should be separately identified in an oriented specimen to determine whether the node is involved by metastatic carcinoma.
- The dissection, examination and block selection should be carried out from one end of the specimen to the other.
- Lymph nodes, less than 5 mm in maximum dimension, will not require slicing.
- Lymph nodes more than 5 mm - Serially slice looking for grossly identifiable deposits. Slice the lymph node(s) at 2 mm intervals perpendicular to the long axis to promote fixation. To avoid distortion of the tissue, large lymph nodes (>15mm) may be cut into 4 mm slices initially, then fixed for 30-60 minutes before slicing at 2 mm intervals. If the lymph node is macroscopically uninvolved the node should be submitted in entirety.
- Macroscopically involved nodes may be bisected along the median plane to demonstrate the relationship of tumour to the capsule. One representative block of a macroscopically involved node is sufficient.
- Where extranodal extension is apparent or suspected, lines of dissection should extend through adjacent tissues to allow microscopic evaluation of extranodal invasion.
- The presence of matted lymph nodes or extension of tumour to the surgical resection margin in axillary clearance specimens is rare but should be reported if apparent.
- If skin is present any abnormal area should be sampled. In the absence of any abnormality one representative block is adequate.
- Be careful to prevent counting a single lymph node as multiple nodes on sliced sections.
- Record details of each cassette in the block key.

### 1.4 Microscopy and conclusion [X]

- Record total number of nodes (this should be according to levels if specified by the surgeon)
- Record number of nodes with metastases
- Record presence of extranodal extension
- If only micro-metastases or isolated tumour cells (ITC) are seen this should be specified.
- In post neoadjuvant therapy specimens, record any treatment effects seen in lymph nodes (treatment effect is defined as areas of scarring, hyalinization, necrosis, extensive myxoid change). Nodal response should be classified as described in section 5.4

- Nodal stage is determined according to the most recent AJCC TNM Classification of axillary lymph nodes (Annexure VII)

### **Summary of items to be included in reports of axillary clearance specimens:**

- Total number of lymph nodes
- Number of lymph nodes with metastases (Specify if only micro-metastases or ITC are present)
- Presence/absence of extra nodal extension
- Nodal AJCC/TNM stage

## **References**

1. Amin MB, Edge S, Greene F, Byrd DR, Brookland RK, Washington MK, Gershenwald JE, Compton CC, Hess KR, et al. (Eds.). AJCC Cancer Staging Manual (8<sup>th</sup> edition). Springer International Publishing: American Joint Commission on Cancer; 2017.
2. Bilous M, Reeve T, Zorbas H, Farshid G, Ahern V, Chirgwin J, Lakhani S, Pike C, Provenzano E, Salisbury E and Tan PH. Invasive breast cancer structured reporting protocol, The Royal College of Pathologists of Australasia, Surry Hills, NSW, 2012. Available at: <https://www.rcpa.edu.au/Manuals/Macroscopic-Cut-Up-Manual/Haematolymphoid/Sentinel-and-regional-lymph-nodes-breast>
3. Blancas I, Garcia- Puche J, Bermejo B, et al. Low number of examined lymph nodes in node- negative breast cancer patient is an adverse prognostic factor. Ann Oncol 2006; 17: 1644-1649. Available at: [https://www.annalsofncology.org/article/S0923-7534\(19\)38066-4/fulltext](https://www.annalsofncology.org/article/S0923-7534(19)38066-4/fulltext) PMID: 16873428
4. The pathology reporting of breast cancer A guide pathologist ,surgeons, radiologist and oncologist . National Breast and Ovarian Cancer Centre and Australian Cancer Network 3<sup>rd</sup> edition. Available at: <https://www.semanticscholar.org/paper/The-pathology-reporting-of-breast-cancer-A-guide/70b02592a10e80a3c62821ed1449fc00f2a1a95a>

## CHAPTER 6

# Handling and reporting of sentinel lymph node biopsy in early breast cancer

---

### 6.1 Introduction

Sentinel nodes may be sent fresh for intraoperative diagnosis or in fixative for routine examination. Each pathology laboratory, in consultation with the surgical team, should determine which method is appropriate for them depending on the resources and expertise available in the hospital and laboratory.

The advantage of intraoperative assessment is that axillary dissection could be avoided if the node is negative for metastasis or axillary dissection can be performed immediately if the node is positive.

Both cytological and frozen section methods of intraoperative assessment for sentinel node provide excellent specificity and acceptable rates of sensitivity. Definite histological assessment is however needed to confirm intraoperative results.

### 6.2 Specimen handling [X]

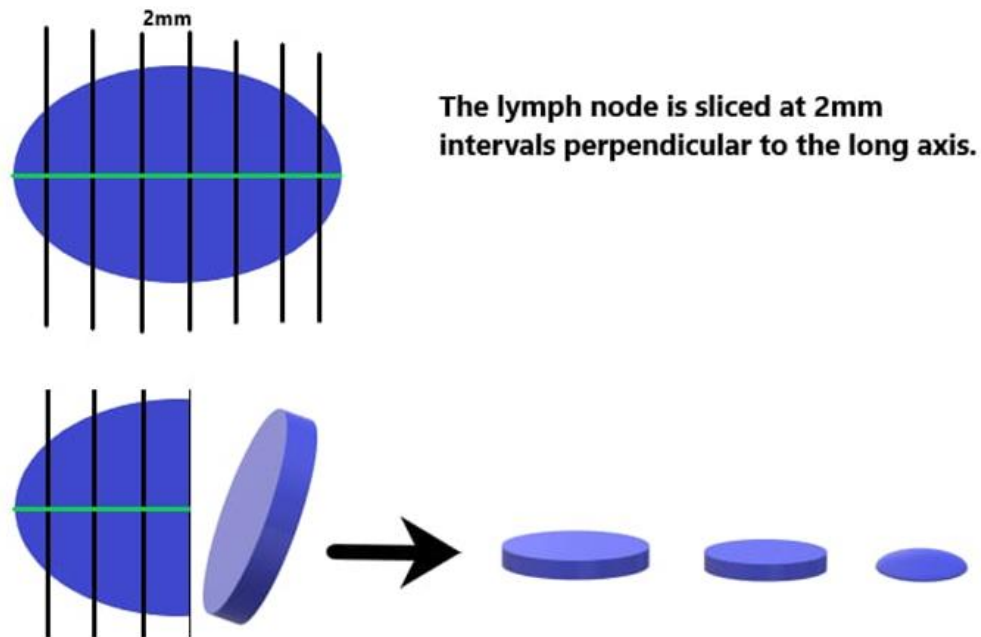
Record the procedure as stated by the surgeon with the laterality. e.g., right axillary sentinel lymph node.

- Gross appearances of the sentinel lymph node should be described, noting particularly the presence of dye. Record the number of lymph nodes and size of each lymph node in three dimensions
- Describe the type of intraoperative consultation performed. e.g., frozen, imprint cytology, crush smears etc.

#### 6.2.1 Handling of intraoperative specimen [X]

- Cut the node into 2mm thick slices perpendicular to long axis (Figure 6.1) and examine carefully for macroscopic evidence of metastasis which may be visible as chalky white firm to hard areas.
- If cytology is required, an imprint can be prepared by pressing the cut surface/s of the node or by making a scraping smear on a glass slide from the cut surface of the sentinel lymph node. The smears are stained using a rapid cytology staining method.

- If facilities for frozen section are available, the entire node or representative slices of the node/s (depending on the size of the node) should be submitted for frozen section examination.
- All tissue should be fixed in formalin subsequently for routine examination.
  - A potential disadvantage of the frozen section technique is that tissue may be lost during the preparation of the frozen section, and care should be taken to minimize this.



**Figure 6.1** Slicing of the sentinel lymph node

### 6.2.2 Handling of formalin fixed specimens [X]

- Macroscopically uninvolved lymph nodes should be serially sliced at 2mm intervals and submitted in their entirety (Figure 6.1).
- Care must be taken to ensure that non-opposing faces of the slices are placed serially in the cassette.
- In macroscopically involved lymph nodes, one representative slice is sufficient to document metastasis.
- Take precautions to prevent cross contamination.
- Record details of each cassette in the block key.

### 6.3 Microscopy and conclusion of formalin fixed sentinel node/s [X]

Examine four non-serial, deep levels of each block and record the following:

- Total number of sentinel nodes
- Number of sentinel nodes with macrometastases (> 2mm)
- Number of sentinel nodes with micrometastases (> 0.2mm to 2mm or more than 200 cells in a single histological cross-section)
- Number of sentinel nodes with isolated tumour cells (ITC) ( $\leq$  0.2mm or  $\leq$  200 cells in a single histological cross - section - this is considered as node negative)
- Nodal stage is documented according to the AJCC/TNM classification of axillary lymph nodes. When categorization is based only on sentinel lymph node biopsy additional designation (sn) is given.

#### Summary of items to be included in reports of sentinel lymph node specimens:

- Total number of sentinel lymph nodes
- Number of lymph nodes with metastases (Specify if only micrometastases or ITC)
- Presence / absence of extranodal extension

### References

1. Amin MB, Edge S, Greene F, Byrd DR, Brookland RK, Washington MK, Gershenwald JE, Compton CC, Hess KR, et al. (Eds.). AJCC Cancer Staging Manual (8<sup>th</sup> edition). Springer International Publishing: American Joint Commission on Cancer; 2017.
2. Bilous M, Reeve T, Zorbas H, Farshid G, Ahern V, Chirgwin J, Lakhani S, Pike C, Provenzano E, Salisbury E and Tan PH. Invasive breast cancer structured reporting protocol, The Royal College of Pathologists of Australasia, Surry Hills, NSW, 2012. Available at: <https://www.rcpa.edu.au/Manuals/Macroscopic-Cut-Up-Manual/Haematolymphoid/Sentinel-and-regional-lymph-nodes-breast>
3. Blancas I, Garcia- Puche J, Bermejo B, et al. Low number of examined lymph nodes in node- negative breast cancer patient is an adverse prognostic factor. Ann Oncol 2006; 17: 1644-1649. Available at: [https://www.annalsofoncology.org/article/S0923-7534\(19\)38066-4/fulltext](https://www.annalsofoncology.org/article/S0923-7534(19)38066-4/fulltext) PMID: 16873428
4. The pathology reporting of breast cancer A guide pathologist ,surgeons, radiologist and oncologist . National Breast and Ovarian Cancer Centre and Australian Cancer Network 3<sup>rd</sup> edition. Available at: <https://www.semanticscholar.org/paper/The-pathology-reporting-of-breast-cancer-A-guide/70b02592a10e80a3c62821ed1449fc00f2a1a95a>

## CHAPTER 7

### Reporting of biomarkers

---

#### 7.1 Introduction

Biomarkers that are tested routinely include oestrogen receptors (ER), progesterone receptors (PR), HER2 and Ki67. The assessment of these biomarkers should be done in the invasive component of the tumour. In the absence of an invasive tumour, assessment of ER and PR is recommended for ductal carcinoma in situ.

When available, the core biopsy is the preferred specimen for assessing biomarker status. However, in some instances testing of biomarkers on the excision or resection specimen may be required. Histologically distinct carcinomas and widely separated carcinomas should each be assessed for biomarkers.

#### 7.2 Types of specimens

- A. Core biopsies
- B. Excision specimens
- C. Mastectomy specimens – pre /post treatment
- D. Excision specimens of recurrences and metastasis e.g., soft tissue / lymph nodes

#### 7.3 Specimen fixation [X]

- Fixatives: 10% neutral buffered formalin [Y]  
10% formalin is currently used in many laboratories, since the above recommended fixative is not widely available.
- Cold ischemia time should be less than 1 hour.
- Fixation time:  
Core biopsies – Minimum of 6 to 8 hours. Not more than 72 hours.  
Excision specimens – Minimum of 24 to 48 hours. Not more than 72 hours.

#### 7.4 Antigen retrieval [X]

- Heat mediated antigen retrieval - pressure cooker or microwave retrieval
- The correct duration of antigen retrieval is critical; if the heating time is too short it can lead to false negatives and an extended retrieval time can lead to false positives.

## 7.5 Controls [X]

- External positive and negative controls for ER/PR and HER2 must be used for each staining run
- Internal controls - Whenever possible a tissue block of tumour with a focus of normal breast tissue should be chosen, as this can function as an internal control.

## 7.6 Scoring [X]

### Hormone receptors

- Hormone receptors are assessed according to the ASCO/CAP guideline and Allred score. Only nuclear staining is considered, and the invasive component should be assessed. In the absence of an invasive component, testing of ductal carcinoma in situ (DCIS) for ER and PR is recommended.
- The Allred score should be used for semiquantitative scoring of ER/PR.
- The current consensus (ASCO/CAP) is that the recommended cut-off point for positivity versus negativity for ER or PR status is greater than or equal to 1% of tumour cells.

### Allred scoring system for ER and PR

Score for Proportion Staining (PS)	+	Score for Staining Intensity (IS)
0 = No nuclear staining		0 = No staining
1 = < 1% nuclei staining *		1 = Weak staining
2 = 1 - 10% nuclei staining **		2 = Moderate staining
3 = 11 - 33% nuclei staining		3 = Strong staining
4 = 34 - 66% nuclei staining		
5 = 67 - 100% nuclei staining		

TOTAL SCORE = PS + IS

Adding the two scores together gives a maximum score of 8.

A total score of 3 or more is taken as positive \*

\* According to the ASCO/CAP guidelines, all cases showing  $\geq 1\%$  of tumour cells positive for ER/PR should be classified as receptor positive regardless of their Allred score. All cases showing  $< 1\%$  of tumour cells positive should be classified as receptor negative regardless of their Allred score.

\*\* There is limited data on endocrine therapy benefit for cancers with 1% to 10% of cells showing nuclear ER positivity. Samples showing staining for ER (not PR) in 1% to 10% of nuclei should be reported using a new reporting category, ER - Low Positive. The status of internal and external controls should be reported for cases with 0% to 10% nuclear staining.

Repeat testing of biomarkers on the surgical excision specimens should be considered based on the clinical and pathological context. Interpretation of ER/PR status should be



done with caution and may need to be repeated if the following situations occur in the core biopsy on which initial ER/PR testing was performed.

- Excessive delay from sample collection to transfer to fixative (cold ischaemia time > 1hr)
- Over fixation of tissue (> 72 hrs in formalin)
- Inadequately fixed tissue (< 6 hrs in fixative)
- Inadequate tumour in the core biopsy
- Presence of artefacts
- When controls show no staining or weak positivity and when adequate tissue is not available in the core for repeat testing
- When internal controls do not show staining
- Negative expression in tumours with low histologic grade e.g.: tubular carcinoma, mucinous carcinoma, classic lobular carcinoma

### Scoring method for HER2

Result category	Score to report	Staining pattern
Negative	0	No staining is seen or incomplete membrane staining that is faintly perceptible and in $\leq 10\%$ of cells
Negative	1+	Incomplete membrane staining that is faintly perceptible and in >10% of cells
Equivocal*	2+	Weak to moderate complete membrane staining in >10% of cells
Positive	3+	Circumferential membrane staining that is complete, intense and in >10% of cells

\* Equivocal results of HER2 needs further testing with FISH. This can be performed on formalin fixed paraffin embedded tissue. A block with adequate tumour should be selected.

Exercise caution in interpreting HER2 in core biopsies in the following situations:

- Excessive delay from sample collection to transfer to fixative (cold ischaemia time > 1 hr)
- Over fixation of tissue (> 72 hrs in formalin)
- Inadequately fixed tissue (< 6 hrs in formalin)
- Excessive artefacts – edge, crush, disruption, necrosis
- Decalcified blocks
- Inappropriate staining of controls
- Over expression in benign elements

### **Ki-67 index**

This is assessed based on a count of at least 500 tumour cells in the peripheral area including hot spots. In ER/PR+ HER2- tumours the Ki-67 proliferation index is used to categorize tumours as luminal A vs luminal B.

## **7.7 Surrogate molecular classification of breast carcinoma by IHC**

Gene expression signatures have been used to classify breast cancer into different molecular subgroups with different survival patterns and prognosis. Studies have shown that surrogate immunohistochemical markers can be used to define subgroups of breast carcinoma with clinical outcomes that are similar, although not identical to those intrinsic subtypes identified by gene expression profiling. Therefore, for the purpose of treatment decision-making and prognostication, tumours are grouped into surrogate intrinsic subtypes, defined by routine histology and immunohistochemistry data (Figure 7.1). At present there is no universally agreed cut off value for Ki67 and PR. However most current guidelines including the WHO classification of tumours 2019 recommend that ER positive/HER2 negative tumours with a Ki-67  $\geq 14\%$  are categorised as luminal B and ER positive/HER2 negative tumours with a Ki-67 proliferation index  $<14\%$  are categorised as luminal A. Most guidelines have adopted the recommendations of the 2013 St Gallen Consensus based on which ER positive/HER2 negative tumours which are PR negative or have a PR  $<20\%$  are categorized as luminal B.

## **7.8 Reporting [X]**

A standard reporting format should be used including the following details:

- Patient identification details
- Lab reference number/IHC Lab reference number
- Type of specimen
- Histological diagnosis
- Scoring results with scoring guidelines
- Status of controls in tumours showing low ER positivity
- The antibodies used
- Date and signature of the histopathologist
- A comment if the tissue is autolyzed.

A proforma for reporting biomarkers has been included in annexure IX.

## Immunohistochemical surrogates for the molecular classification of breast carcinoma

Luminal	ER Positive	HER2 Negative	Ki-67:low PR:positive	Luminal A-like	
		HER2 Amplified	Ki-67:high and/or PR:negative or low	Luminal B-like (HER2 negative)	
			Ki-67:any PR:any	Luminal B-like (HER2 positive)	
ER and PR Negative	HER2 Amplified	Ki-67:any	HER2 positive (non luminal)		
	HER2 Negative	Ki-67:any	Triple Negative *		

★ Triple negative breast cancer is a heterogeneous group of tumours that has been divided into subtypes based on gene expression data.

★★ In general, it is predicted to have worsening outcomes along the direction of the arrow. However triple negative breast cancer is a heterogeneous group with different molecular subtypes that have different survival patterns and prognoses. Other clinicopathological parameters such as staging should be considered in prognostication of individual tumours.

**Figure 7.1** Molecular subtypes of breast carcinoma based on immunohistochemistry surrogate markers

**Reporting guidelines****ASCO/CAP Guideline Update 2020 for ER and PR testing****Estrogen receptor**

Positive >10% of cells demonstrate nuclear positivity of any intensity

Low positive 1-10% of cells with nuclear positivity of any intensity

Negative less than 1%

**Progesterone receptor**

Positive >1% of cells demonstrate nuclear positivity of any intensity

Negative less than 1%

**Allred Scoring System for ER and PR**

Total score = Proportion score (\_\_\_/5) + Intensity score (\_\_\_/3)

**ASCO/CAP Guideline Update 2018 for HER2 testing**

<b>Result category</b>	<b>Score to report</b>	<b>Staining pattern</b>
Negative	0	No staining is seen or incomplete membrane staining that is faintly perceptible and in $\leq 10\%$ of cells
Negative	1+	Incomplete membrane staining that is faintly perceptible and in $>10\%$ of cells
Equivocal	2+	Weak to moderate complete membrane staining in $>10\%$ of cells
Positive	3+	Circumferential membrane staining that is complete, intense and in $>10\%$ of cells

**Ki-67 Proliferation index** \_\_\_ %

## References

1. Allison KH, M. Hammond MEH, Dowsett M et al. Estrogen and Progesterone Receptor Testing in Breast Cancer: ASCO/CAP Guideline Update. *J Clin Oncol* 2020;38:1346-1366. DOI: 10.1200/JCO.19.02309. PMID: 31928404
2. Ellis IO, Carder P, Hales S et al. Pathology reporting of breast disease in surgical excision specimens incorporating the dataset for histological reporting of breast cancer. Royal College of Pathologists, 2016. Available at : [https://www.rcpath.org/uploads/assets/7763be1c-d330-40e8-95d08f955752792a/G148\\_BreastDataset-hires-Jun16.pdf](https://www.rcpath.org/uploads/assets/7763be1c-d330-40e8-95d08f955752792a/G148_BreastDataset-hires-Jun16.pdf)
3. Goldhirsch A, Winer EP, Coates AS, Gelber RD, Piccart-Gebhart M, Thürlimann B, Senn HJ; Panel members: Personalizing the treatment of women with early breast cancer: highlights of the St Gallen International Expert Consensus on the Primary Therapy of Early Breast Cancer 2013. *Ann Oncol.* 2013; 24: 2206-2223. DOI: doi:10.1093/annonc/mdt303.
4. Wolff AC, Hammond MEH, Allison KH et al. Human Epidermal Growth Factor Receptor 2 Testing in Breast Cancer American Society of Clinical Oncology/College of American Pathologists Clinical Practice Guideline Focused Update. *Arch Pathol Lab Med* 2018; 142: 1364-1382. DOI: 10.5858/arpa.2018-0902-SA. PMID: 29846104
5. WHO Classification of Tumours Editorial Board. Breast tumours. Lyon (France): International Agency for Research on Cancer; 2019. (WHO classification of tumours series, 5<sup>th</sup> ed.; vol. 2).

## CHAPTER 8

### Other ancillary tests

---

Gene expression profiles, such as MammaPrint, Oncotype DX Recurrence Score, Prosigna, Endopredict and Breast Cancer Index may be used to gain additional prognostic and/or predictive information to complement pathology assessment and to predict the benefit of adjuvant chemotherapy.

All tests except MammaPrint were designed for patients with ER-positive early breast cancer only. Although these tests are currently unavailable in the local setting, pathologists may be requested to provide material for testing.

Oncotype DX can be performed on formalin fixed paraffin embedded tissue and although it is currently not a requirement, results of Oncotype DX have also been incorporated by the AJCC into the genomic profile to determine pathologic prognostic score.

BRCA mutation, although not technically an ancillary test (since it is not tested on tumour tissue) may be recommended in some instances, including young breast carcinoma, bilateral breast carcinoma, a strong family history of breast carcinoma and some cases of triple negative breast carcinoma, following evaluation by a clinical geneticist.

### References

1. Amin MB, Edge S, Greene F, Byrd DR, Brookland RK, Washington MK, Gershenwald JE, Compton CC, Hess KR, et al. (Eds.). AJCC Cancer Staging Manual (8<sup>th</sup> edition). Springer International Publishing: American Joint Commission on Cancer; 2017
2. Pascal P et al. Clinical practice guidelines for BRCA1 and BRCA2 genetic testing. *European Journal of Cancer* 2021;146:30 – 47. <https://doi.org/10.1016/j.ejca.2020.12.023>

## Annexure I

## Sample requisition form

<b>Department of Histopathology</b>		<b>For laboratory use only</b>			
Name, Address and Contact Details of Institution		Lab reference No./Barcode			
Logo of institution	Urgent <input type="checkbox"/>	Routine <input type="checkbox"/>	Date and time of reception		
<b>Name</b>		<b>Date of birth</b>			
<b>Age</b>		<b>NIC number</b>			
<b>Gender</b>		<b>BHT/Clinic No:</b>			
<b>Ward/Clinic</b>		<b>Date and time of specimen collection</b>			
<b>Patients contact number</b>					
<b>Clinical details</b>					
<b>Number and type of specimen/s</b>	1. 2. 3.				
<b>Site of lesion</b>	Side				
	Location in the breast				
<b>Orientation</b>	Margin 1				
	Margin 2				
	Nipple margin				
<b>Preoperative pathological diagnosis with laboratory reference number</b>	Cytology with lab reference number				
	Histology with lab reference number	Diagnosis	Grade		
<b>Preoperative radiology</b>	Diagnosis /BIRADS				
	Size of tumour				
<b>Neoadjuvant therapy Given</b>	Duration				
	No. of cycles				
	Date of completion				
	Clinical response	Complete / Partial / No response			
<b>Not given</b>					
<b>Biomarkers done on core biopsy</b>	Yes (Ref No)	ER	PR	HER2	Ki-67
	No				
<b>Diagram</b>					
<b>Skin changes</b>	Nipple retraction <input type="checkbox"/> Peau d' orange <input type="checkbox"/> Nodule <input type="checkbox"/> Ulceration <input type="checkbox"/> Evidence of inflammatory carcinoma <input type="checkbox"/>				
<b>Time of specimen harvesting</b>	<b>Time of transfer of specimen to formalin</b>				
<b>Referring consultant</b>					
<b>Name and designation of requesting medical officer</b>					
<b>Signature</b>			<b>Contact number</b>		

## Annexure II

**Checklist to be filled before sending the specimens from the surgical theatre (to be checked on acceptance to the laboratory)**

NO.	ITEM	THEATRE	LABORATORY
1	Properly filled requisition form		
2	Suitable container/s		
3	Correct labelling of the container/s		
4	Orientation of the specimen/s according to agreed protocol		
5	Adequate volume of recommended fixative		
6	Date and time of specimen harvest		
7	Date and time of receipt to the laboratory		
8	Name and designation of the person who completed the check list		

## Annexure III

**Note:** It is recommended that the pathologist use the latest WHO classification for tumour typing. The latest classification at the time of publication is given below.

### World Health Organization classification of epithelial tumours of the breast 2019

#### Benign epithelial proliferations and precursors

- Usual ductal hyperplasia
- Columnar cell lesions, including flat epithelial atypia
- Atypical ductal hyperplasia

#### Adenosis and benign sclerosing lesions

- Sclerosing adenosis
- Apocrine adenoma
- Microglandular adenosis
- Radial scar / complex sclerosing lesion

#### Adenomas

- Tubular adenoma NOS
- Lactating adenoma
- Duct adenoma NOS

#### Epithelial-myoepithelial tumours

- Pleomorphic adenoma
- Adenomyoepithelioma NOS
- Adenomyoepithelioma with carcinoma



- Epithelial-myoepithelial carcinoma

### **Papillary neoplasms**

- Intraductal papilloma
- Ductal carcinoma in situ, papillary
- Encapsulated papillary carcinoma
- Encapsulated papillary carcinoma with invasion
- Solid papillary carcinoma in situ
- Solid papillary carcinoma with invasion
- Intraductal papillary adenocarcinoma with invasion

### **Non-invasive lobular neoplasia**

- Atypical lobular hyperplasia
- Lobular carcinoma in situ NOS
- Classic lobular carcinoma in situ
- Florid lobular carcinoma in situ
- Lobular carcinoma in situ, pleomorphic

### **Ductal carcinoma in situ (DCIS)**

- Intraductal carcinoma, non-infiltrating, NOS
- DCIS of low nuclear grade
- DCIS of intermediate nuclear grade
- DCIS of high nuclear grade

### **Invasive Carcinoma of the Breast**

- Infiltrating duct carcinoma NOS
- Oncocytic carcinoma
- Lipid-rich carcinoma
- Glycogen-rich carcinoma
- Sebaceous carcinoma
- Lobular carcinoma NOS
- Tubular carcinoma
- Cribriform carcinoma NOS
- Mucinous adenocarcinoma
- Mucinous cystadenocarcinoma NOS
- Invasive micropapillary carcinoma of breast
- Apocrine adenocarcinoma
- Metaplastic carcinoma NOS

### **Rare and salivary gland-type tumours**

- Acinar cell carcinoma
- Adenoid cystic carcinoma
- Classic adenoid cystic carcinoma
- Solid-basaloid adenoid cystic carcinoma
- Adenoid cystic carcinoma with high-grade transformation
- Secretory carcinoma
- Mucoepidermoid carcinoma
- Polymorphous adenocarcinoma

- Tall cell carcinoma with reversed polarity

### **Neuroendocrine neoplasms**

- Neuroendocrine tumour NOS
- Neuroendocrine tumour, grade 1
- Neuroendocrine tumour, grade 2
- Neuroendocrine carcinoma NOS
- Neuroendocrine carcinoma, small cell
- Neuroendocrine carcinoma, large cell

### **References**

1. College of American Pathologists. Protocol for the Examination of Resection Specimens from Patients with Invasive Carcinoma of the Breast. February 2020. Available at: <https://documents.cap.org/protocols/cp-breast-invasive-resection-20-4400.pdf>
2. WHO Classification of Tumours Editorial Board. Breast tumours. Lyon (France): International Agency for Research on Cancer; 2019. (WHO classification of tumours series, 5<sup>th</sup> ed.; vol. 2).

## Annexure IV

### Breast cancer grading

The Nottingham grading system involves the assessment of three components of tumour morphology: tubule / acinar / glandular formation, nuclear atypia / pleomorphism and frequency of mitoses. Each is scored from 1 to 3.

<b>Tubule / acinar formation</b>	<p>Assessment of tubular differentiation is made on the overall appearances of the tumour. All parts of the tumour are scanned, and the proportion occupied by tumour islands showing clear acinar or gland formation or defined tubular structures with a central luminal space is assessed semi-quantitatively. This assessment is generally carried out during the initial low power scan of the tumour.</p> <p><b>Score 1:</b> &gt;75% of tumour forming tubular structures  <b>Score 2:</b> 10–75% of tumour  <b>Score 3:</b> &lt;10% of tumour.</p>
<b>Nuclear atypia / pleomorphism</b>	<p>Nuclear appearances are evaluated at the periphery and / or least differentiated area of the tumour.</p> <p><b>Score 1:</b> Nuclei small with little increase in size (&lt;1.5 x normal) in comparison with normal breast epithelial cells, regular outlines, uniform nuclear chromatin, little variation in size.  <b>Score 2:</b> Cells larger than normal (1.5 – 2 x normal) with open vesicular nuclei, visible nucleoli and moderate variability in both size and shape.  <b>Score 3:</b> Large vesicular nuclei (&gt; 2 normal), often with prominent nucleoli, exhibiting marked variation in size and shape, occasionally with very large and bizarre forms.</p>
<b>Mitoses</b>	<p>The mitosis score depends on the number of mitoses per 10 high power fields. The size of high-power fields is variable in different microscopes, therefore it is necessary to standardize the mitotic count according to the size of the high-power field of the microscope used. If there is variation in the number of mitoses in different areas of the tumour, the least differentiated area (i.e., with the highest mitotic count) should be assessed. Only definite mitotic figures (in any phase of the growth cycle) should be counted. Hyperchromatic nuclei and /or apoptotic nuclei should not be scored. Poor quality fixation can result in underscoring of</p>

	mitotic frequency; optimal fixation is essential. Scoring thresholds are given in the table. To standardize the reporting of mitotic counts it is recommended to express the count as a defined area expressed in mm <sup>2</sup> instead of 10 high power fields.
<b>Overall grade</b>	The scores for tubule formation, nuclear pleomorphism and mitoses are then added together and assigned to grades, as below: <b>Grade 1</b> = Scores of 3–5 <b>Grade 2</b> = Scores of 6 or 7 <b>Grade 3</b> = Scores of 8 or 9.

**Table 4A1.** Mitotic count by 40x lens microscopic field diameter

Field diameter (mm)	Field area (mm <sup>2</sup> )	Score 1	Score 2	Score 3
<b>0.40</b>	0.126	up to 4	5 to 9	10 or more
<b>0.41</b>	0.132	up to 4	5 to 9	10 or more
<b>0.42</b>	0.138	up to 5	6 to 10	11 or more
<b>0.43</b>	0.145	up to 5	6 to 10	11 or more
<b>0.44</b>	0.152	up to 5	6 to 11	12 or more
<b>0.45</b>	0.159	up to 5	6 to 11	12 or more
<b>0.46</b>	0.166	up to 6	7 to 12	13 or more
<b>0.47</b>	0.173	up to 6	7 to 12	13 or more
<b>0.48</b>	0.181	up to 6	7 to 13	14 or more
<b>0.49</b>	0.188	up to 6	7 to 13	14 or more
<b>0.50</b>	0.196	up to 7	8 to 14	15 or more
<b>0.51</b>	0.204	up to 7	8 to 14	15 or more
<b>0.52</b>	0.212	up to 7	8 to 15	16 or more
<b>0.53</b>	0.221	up to 8	8 to 16	17 or more
<b>0.54</b>	0.229	up to 8	8 to 16	17 or more
<b>0.55</b>	0.237	up to 8	9 to 17	18 or more

<b>0.56</b>	0.246	up to 8	9 to 17	18 or more
<b>0.57</b>	0.255	up to 9	9 to 18	19 or more
<b>0.58</b>	0.264	up to 9	10 to 19	20 or more
<b>0.59</b>	0.273	up to 9	10 to 19	20 or more
<b>0.60</b>	0.283	up to 10	10 to 20	21 or more
<b>0.61</b>	0.292	up to 10	10 to 21	22 or more
<b>0.62</b>	0.302	up to 11	12 to 22	23 or more
<b>0.63</b>	0.312	up to 11	12 to 22	23 or more
<b>0.64</b>	0.322	up to 11	12 to 23	24 or more
<b>0.65</b>	0.332	up to 12	13 to 24	25 or more
<b>0.66</b>	0.342	up to 12	13 to 24	25 or more
<b>0.67</b>	0.352	up to 12	13 to 25	26 or more
<b>0.68</b>	0.363	up to 13	13 to 26	27 or more
<b>0.69</b>	0.374	up to 13	13 to 27	28 or more

$$\text{Field diameter} = \frac{\text{Field number}}{\text{Magnification of objective}}$$

For example, if the microscope's eye piece reads 10x/20, the field number is 20 and eyepiece magnification is 10. Therefore, the field diameter when using the 40x objective is:  $20/40 = 0.5$  mm. This corresponds to a field area of  $0.196 \text{ mm}^2$ . 10 fields with a field diameter of 0.5 mm would have a field area of  $1.96 \text{ mm}^2$ .

## References

1. Elston CW, Ellis IO. Pathological prognostic factors in breast cancer. The value of histological grade in breast cancer: experience from a large study with long-term follow-up. *Histopathology* 1991; 19: 403–410. DOI: DOI: 10.1111/j.1365-2559.1991.tb00229.x. PMID: 1757079
2. Ellis IO, Carder P, Hales S et al. Pathology reporting of breast disease in surgical excision specimens incorporating the dataset for histological reporting of breast cancer. Royal College of Pathologists, 2016. Available at : [https://www.rcpath.org/uploads/assets/7763be1c-d330-40e8-95d08f955752792a/G148\\_BreastDataset-hires-Jun16.pdf](https://www.rcpath.org/uploads/assets/7763be1c-d330-40e8-95d08f955752792a/G148_BreastDataset-hires-Jun16.pdf)

## Annexure V

### Nuclear grade of ductal carcinoma in situ

Feature	Grade I (Low)	Grade II (Intermediate)	Grade III (High)
<b>Pleomorphism</b>	Monotonous (monomorphic)	Intermediate	Markedly pleomorphic
<b>Size</b>	1.5 to 2 x the size of a normal red blood cell or a normal duct epithelial cell nucleus	Intermediate	>2.5 x the size of a normal red blood cell or a normal duct epithelial cell nucleus
<b>Chromatin</b>	Usually diffuse, finely dispersed chromatin	Intermediate	Usually vesicular with irregular chromatin distribution
<b>Nucleoli</b>	Only occasional	Intermediate	Prominent, often multiple
<b>Mitoses</b>	Only occasional	Intermediate	May be frequent
<b>Orientation</b>	Polarized toward luminal spaces	Intermediate	Usually not polarized toward the luminal space

### References

1. College of American Pathologists. Protocol for the Examination of Resection Specimens from Patients with Invasive Carcinoma of the Breast. February 2020. Available at: <https://documents.cap.org/protocols/cp-breast-invasive-resection-20-4400.pdf>
2. Schwartz GF, Lagios MD, Carter D, et al. Consensus conference on the classification of ductal carcinoma in situ. *Cancer*. 1997;80:1798-1802. DOI: 10.1002/(sici)1097-0142(19971101)80:9<1798::aid-cnrcr15>3.0.co;2-0. PMID: 9351550

## Annexure VI

### Guideline for assessment of tumour infiltrating lymphocytes (TILs)

- TILs should be reported for the stromal compartment (= % stromal TILs).
- The denominator used to determine the % stromal TILs is the area of stromal tissue not the number of stromal cells.
- TILs should be evaluated within the borders of the invasive tumour.
- Exclude TILs outside of the tumour border and around DCIS and normal lobules.
- Exclude TILs in tumour zones with crush artifacts, necrosis, regressive hyalinization as well as in the previous core biopsy site.
- All mononuclear cells (including lymphocytes and plasma cells) should be scored, but polymorphonuclear leukocytes are excluded.
- One section (4–5 µm, magnification ×200–400) per patient is currently considered to be sufficient.
- Full sections are preferred over biopsies whenever possible.
- Cores can be used in the pretherapeutic neoadjuvant setting
- A full assessment of average TILs in the tumour area by the pathologist should be used, without focusing on hotspots.
- Scoring as a continuous variable is recommended.
- For assessment of percentage values, the dissociated growth pattern of lymphocytes needs to be considered. Lymphocytes typically do not form solid cellular aggregates; therefore, the designation '100% stromal TILs' would still allow some empty tissue space between the individual lymphocytes.

International Guidelines on the assessment of TILs in breast cancer and an online training tool are available at <https://www.tilsinbreastcancer.org>

### References

1. Salgado R, Denkert C, Demaria S et al. The evaluation of tumour-infiltrating lymphocytes (TILs) in breast cancer: recommendations by an International TILs Working Group 2014. *Annals of Oncology* 26: 259–271, 2015. doi:10.1093/annonc/mdu450.

## Annexure VII

### Note:

- It is recommended that the pathologist use the latest TNM/AJCC staging classification for staging. The latest TNM staging at the time of publication is given below.
- Reporting of pT, pN, and (when applicable) pM categories is based on information available to the pathologist at the time the report is issued.

### Pathologic stage classification (pTNM, AJCC 8<sup>th</sup> Edition)

#### Primary Tumour (pT)

##### TNM descriptors (required only if applicable)

- m** Multiple foci of invasive carcinoma
- r** Recurrent
- y** Post-treatment

**pTX** Primary tumour cannot be assessed

**pT0** No evidence of primary tumour \*

**pTis (DCIS)** Ductal carcinoma in situ \*

**pTis (Paget)** Paget disease of the nipple not associated with invasive carcinoma and/or DCIS in the underlying breast parenchyma \*\*

**pT1** Tumour ≤20 mm in greatest dimension

**pT1mi** Tumour ≤1 mm in greatest dimension

**pT1a** Tumour >1 mm but ≤5 mm in greatest dimension (round any measurement >1.0-1.9 mm to 2 mm)

**pT1b** Tumour >5 mm but ≤10 mm in greatest dimension

**pT1c** Tumour >10 mm but ≤20 mm in greatest dimension

**pT2** Tumour >20 mm but ≤50 mm in greatest dimension

**pT3** Tumour >50 mm in greatest dimension

**pT4** Tumour of any size with direct extension to the chest wall and / or to the skin (ulceration or skin nodules) \*\*\*

**pT4a** Extension to the chest wall; invasion or adherence to pectoralis muscle in the absence of invasion of chest wall structures does not qualify as T4



<b>pT4b</b>	Ulceration and/or ipsilateral macroscopic satellite nodules and/or oedema (including peau d'orange) of the skin that does not meet the criteria for inflammatory carcinoma
<b>pT4c</b>	Both T4a and T4b are present
<b>pT4d</b>	Inflammatory carcinoma ****
<p>* These categories should only be used in the setting of preoperative (neoadjuvant) therapy for which a previously diagnosed invasive carcinoma is no longer present after treatment. Patients with pathological complete response (absence of residual invasive carcinoma in both the breast and lymph nodes) should be categorized as ypT0N0 or ypTisN0, not ypTX.</p> <p>** Carcinomas in the breast parenchyma associated with Paget disease are categorized based on the size and characteristics of the parenchymal disease, although the presence of Paget disease should still be noted.</p> <p>*** Invasion of the dermis alone does not qualify as pT4.</p> <p>**** Inflammatory carcinoma requires the presence of clinical findings of erythema and oedema involving at least one-third or more of the skin of the breast.</p>	
<b>Regional lymph nodes (pN)</b>	
<b>Regional lymph nodes modifier (required only if applicable)</b>	
<b>sn</b>	Sentinel node(s) evaluated. If 6 or more nodes (sentinel or non-sentinel) are removed, this modifier should <i>not</i> be used.
<b>f</b>	Nodal metastasis confirmed by fine needle aspiration or core needle biopsy
<b>Note:</b>	
<ul style="list-style-type: none"> <li>▪ The (sn) modifier is added to the N category when a sentinel node biopsy is performed (using either dye or tracer) and fewer than six lymph nodes are removed (sentinel and non-sentinel).</li> <li>▪ The (f) modifier is added to the N category to denote confirmation of metastasis by fine needle aspiration/core needle biopsy with NO further resection of nodes.</li> </ul>	
<b>pNX</b>	Regional lymph nodes cannot be assessed (e.g., not removed for pathological study or previously removed)
<b>pN0</b>	No regional lymph node metastasis identified or ITCs only *
<b>pN0 (i+)</b>	ITCs only (malignant cell clusters no larger than 0.2 mm) in regional lymph node(s)

<b>pN0 (mol+)</b>	Positive molecular findings by reverse transcriptase polymerase chain reaction (RT-PCR); no ITCs detected
<b>pN1mi</b>	Micrometastases (approximately 200 cells, larger than 0.2 mm, but none larger than 2.0 mm)
<b>pN1a</b>	Metastases in 1 to 3 axillary lymph nodes, at least 1 metastasis larger than 2.0 mm **
<b>pN1b</b>	Metastases in ipsilateral internal mammary sentinel nodes, excluding ITCs
<b>pN1c</b>	pN1a and pN1b combined
<b>pN2a</b>	Metastases in 4 to 9 axillary lymph nodes (at least 1 tumour deposit larger than 2.0 mm)
<b>pN2b</b>	Metastases in clinically detected internal mammary lymph nodes with or without microscopic confirmation; with pathologically negative axillary nodes
<b>pN3a</b>	Metastases in 10 or more axillary lymph nodes (at least 1 tumour deposit larger than 2.0 mm) or metastases to the infraclavicular (Level III axillary lymph) nodes **
<b>pN3b</b>	pN1a or pN2a in the presence of cN2b (positive internal mammary nodes by imaging); or pN2a in the presence of pN1b
<b>pN3c</b>	Metastases in ipsilateral supraclavicular lymph nodes

\* Isolated tumour cells (ITCs) are defined as small clusters of cells not greater than 0.2 mm or single tumour cells, or a cluster of fewer than 200 cells in a single histologic cross-section. ITCs may be detected by routine histology or by immunohistochemical (IHC) methods. Nodes containing only ITCs are excluded from the total positive node count for purposes of N classification but should be included in the total number of nodes evaluated.

\*\*If more than 200 individual tumour cells are identified as single dispersed tumour cells or as a nearly confluent elliptical or spherical focus in a single histologic section of a lymph node, the node should be classified as containing a micrometastasis (pN1mi). Cells in different lymph node cross-sections or longitudinal sections or levels of the block are not added together; the 200 cells must be in a single node profile even if the node has been thinly sectioned into multiple slices.

### Distant metastasis (pM)

<b>pM0</b>	No distant metastasis
<b>pM1</b>	Histologically proven metastases larger than 0.2 mm Specify site, if known: _____

## Prognostic stage group

The AJCC recommends that prognostic stage group tables are used as the primary staging system in countries where biomarker tests are routinely performed for patient care. For each combination of T, N, M, Grade, ER, PR, HER2 there is an assigned clinical prognostic stage group and pathological prognostic stage group.

Pathological prognostic stage group applies to patients treated with breast cancer treated with surgery as the initial treatment. It includes information used for clinical staging, findings at and surgery and pathological findings from the surgical resection including T, N, M stage, grade, ER, PR and HER status. When available the genomic profile determined by Oncotype DX score can also be incorporated. Tables that can be used to determine the prognostic stage group are available in the AJCC Staging Manual and summarized below (Figure VIIA1).

Patients treated with neoadjuvant therapy are not assigned a pathological prognostic stage. The AJCC recommends that the clinical prognostic stage and observed degree of response to treatment are documented for these cases.

			ER+, PR+, HER2+	ER+, PR+, HER2-	ER+/PR-, HER2+	ER-/PR+, HER2+	ER-, PR-, HER2+	ER+, PR-, HER2-	ER-, PR+, HER2-	ER-, PR-, HER2-	Anatomic stage
TisN0	M0	G1-3	0	0	0	0	0	0	0	0	0
T1N0 T0N1mi T1N1mi		G1	IA	IA	IA	IA	IA	IA	IA	IA	IA
		G2	IA	IA	IA	IA	IA	IA	IA	IB	IA
		G3	IA	IA	IA	IA	IA	IA	IA	IB	IA
T0N1 T1N1 T2N0		G1	IA	IA	IB	IB	IIA	IB	IB	IIA	IIA
		G2	IA	IA	IB	IB	IIA	IIA	IIA	IIA	IIA
		G3	IA	IB	IIA	IIA	IIA	IIA	IIA	IIA	IIA
T2N1 T3N0		G1	IA	IA	IIIB	IIIB	IIIB	IIIB	IIIB	IIIB	IIIB
		G2	IB	IB	IIIB	IIIB	IIIB	IIIB	IIIB	IIIB	IIIB
		G3	IB	IIA	IIIB	IIIB	IIIB	IIIB	IIIB	IIIA	IIIB
T0N2 T1N2 T2N2 T3N1 T3N2		G1	IB	IB	IIIA	IIIA	IIIA	IIIA	IIIA	IIIA	IIIA
		G2	IB	IB	IIIA	IIIA	IIIA	IIIA	IIIA	IIIB	IIIA
		G3	IIA	IIIB	IIIA	IIIA	IIIA	IIIA	IIIA	IIIC	IIIA
T4N0 T4N1 T4N2 AnyN3		G1	IIIA	IIIA	IIIB	IIIB	IIIB	IIIB	IIIB	IIIB	IIIB
		G2	IIIA	IIIA	IIIB	IIIB	IIIB	IIIB	IIIB	IIIC	IIIB
		G3	IIIB	IIIB	IIIB	IIIB	IIIB	IIIC	IIIC	IIIC	IIIB
Any	M1	Any	IV	IV	IV	IV	IV	IV	IV	IV	

**Figure VIIA1.** Pathologic Prognostic Stage \*

\* pT1, pT2, pN0, M0, ER+, and HER2- cancers are assigned as Pathologic Prognostic Stage group IA when Oncotype DX recurrence score is less than 11.

This figure was obtained from an open access article published in the Korean Journal of Radiology (Koh J, Kim MJ. Introduction of a New Staging System of Breast Cancer for Radiologists: An Emphasis on the Prognostic Stage. Korean J Radiol. 2019;20(1):69-82. doi:10.3348/kjr.2018.0231) and distributed under the terms of the Creative Commons Attribution Non-Commercial License (<http://creativecommons.org/licenses/by-nc/4.0/>) which permits unrestricted non-commercial use, distribution, and reproduction in any medium, provided the original work is properly cited.

## References

1. Amin MB, Edge S, Greene F, Byrd DR, Brookland RK, Washington MK, Gershenwald JE, Compton CC, Hess KR, et al. (Eds.). AJCC Cancer Staging Manual (8<sup>th</sup> edition). Springer International Publishing: American Joint Commission on Cancer; 2017
2. College of American Pathologists. Protocol for the Examination of Resection Specimens from Patients with Invasive Carcinoma of the Breast. February 2020. Available at: <https://documents.cap.org/protocols/cp-breast-invasive-resection-20-4400.pdf>
3. Koh J, Kim MJ. Introduction of a New Staging System of Breast Cancer for Radiologists: An Emphasis on the Prognostic Stage. Korean J Radiol. 2019;20(1):69-82. doi:10.3348/kjr.2018.0231

## Annexure VIII

### Residual cancer burden (RCB) calculator

The RCB system calculates a prognostic score based on:

- A two-dimensional measurement of the tumour bed demarcated by residual carcinoma (figure 4.1)
- The average residual tumour cellularity (invasive and in situ disease). Cellularity estimates are to the nearest 10%, with additional selections of 1% and 5% for very low cellularity.
- The percentage of residual disease that represents in situ disease
- The number of positive lymph nodes
- The diameter of the largest metastatic focus, inclusive of intervening treatment-related fibrosis.

A mathematical formula combines these variables into a continuous index to define four RCB categories;

- RCB-0 for pCR (pathological complete response)
- RCB-1-3 represent progressively greater extents of residual cancer.

A web-based calculator and detailed instructions including explanatory videos are publicly available to calculate the RCB scores.

<http://www3.mdanderson.org/app/medcalc/index.cfm?pagename=jsconvert3>

## Annexure IX

### PROFORMAS FOR REPORTING

#### 9.1 Proforma for reporting core biopsies with breast carcinoma

##### History

Site of biopsy (Side and quadrant):

Presence of microcalcifications:

##### Macroscopic appearance

Number of cores:

Length of cores in mm:

##### Microscopic appearance

(An adequate microscopic description should be provided including the following core items)

Histological type:

Provisional grade: Nottingham grade 1 / 2 / 3

Lymphovascular invasion: present / not identified

DCIS / Pleomorphic LCIS: present / not identified

- If DCIS is present
  - Nuclear grade – low / intermediate / high
  - Architectural type/s
  - Necrosis (comedo / punctate)
  - Microcalcification (present / not identified)

##### Conclusion

Diagnosis:

- Invasive carcinoma (specify type)
- Ductal carcinoma in situ (specify grade)

B-category: B5a / B5b / B5c

##### Block for biomarker studies

Biomarker status when available (according to proforma below)

##### Comment (include if necessary)

e.g., adequacy of specimen for typing, grading, biomarker studies

## 9.2 Proforma for reporting of therapeutic excisions / mastectomy

### Macroscopic appearance

- Type of specimen/s
  - Dimensions of specimen
  - Presence of skin
  - Dimensions of skin
  - Skin/Nipple abnormalities
- Location of tumour/s
  - Size of tumour/s
  - Distance between tumours if multiple
  - Distance from tumour to margins
- *For specimens following neoadjuvant therapy:*
  - Location of tumour bed
  - Size of tumour bed
- Lymph nodes:
  - Type of specimen – axillary clearance / sentinel lymph node biopsy
  - Size of specimen
  - Number of lymph nodes retrieved
  - Presence of matted lymph nodes

### Microscopic appearance

- Tumour type
- Tumour grade
- Invasive tumour size
- Whole tumour size
- In-situ component (DCIS and pleomorphic LCIS)
- Tumour extent (localized vs. multiple tumours)
- Tumour extension (in mastectomy)
- Nipple – Paget disease - present / not identified
- Skin – involved by tumour / not involved
- Tumour infiltrating lymphocytes **[Y]**
- Lymphovascular invasion
- Dermal lymphovascular invasion (in mastectomy)
- Status of excision margins
- Non-neoplastic breast tissue
- Additional pathological findings e.g. microcalcification
- *For specimens following neoadjuvant therapy in addition to items listed above:*
  - Pathological complete response or not
  - Size of residual tumour
  - Cellularity of residual tumour

- Percentage of tumour remaining in the tumour bed
- Type of response – necrosis/fibrosis
- Lymph nodes: (categorize according to levels of axillary clearance if specified)
  - Total number of lymph nodes
  - Number of lymph nodes with metastases
  - Specify if only micro-metastases or isolated tumour cells (ITC) are seen
  - Extranodal extension
- *For lymph nodes following neoadjuvant therapy in addition to items listed above:*
  - Number of nodes with residual tumour and no histologic evidence of treatment response
  - Number of nodes with residual tumour and histological evidence of treatment response
  - Number of nodes with histological evidence of treatment response but no residual tumour
  - Size of the largest residual metastasis in lymph nodes

### Conclusion

- Tumour type
- Tumour size
- Grade
- DCIS
- Lymphovascular invasion
- Status of excision margins
- Lymph node status
- Tumour and nodal response to therapy (Following neoadjuvant treatment)
- Results of biomarkers
- TNM stage
- Pathological prognostic stage group **M**

### 9.3 Proforma for reporting of biomarkers

<b>Estrogen Receptor (ER)</b>	Positive / Low positive / Negative *			
If negative or low positive - state of internal controls	Internal control cells present and stain as Expected / Internal control cells absent			
<b>Progesterone Receptor (PR)</b>	Positive / Negative *			
<b>Allred Score</b>	Percentage score: Intensity score: Total score:			
<b>HER2</b>	Positive / Equivocal / Negative Score:			
<b>Ki-67 proliferation index</b>	_____ %			
<b>Comment</b>	(Include if necessary)			
<b>BIOMARKER</b>	<b>ER</b>	<b>PR</b>	<b>HER2</b>	<b>KI-67</b>
<b>IHC Lab</b>				
<b>Antibody used</b>				
<b>IHC Lab Reference No</b>				

\* Allison KH et al. Estrogen and Progesterone Receptor Testing in Breast Cancer: ASCO/CAP Guideline Update. J Clin Oncol 2020;38:1346-1366. DOI: 10.1200/JCO.19.02309. PMID: 31928404

#### Suggested comments

- **Low Positive ER:** “The cancer in this sample has a low level (1-10%) of ER expression by IHC. There are limited data on the overall benefit of endocrine therapies for patients with low level (1-10%) ER expression, but they currently suggest possible benefit, so patients are considered eligible for endocrine treatment. There are data that suggest invasive cancers with these results are heterogeneous in both behaviour and biology and often have gene expression profiles more like ER negative cancers.”
- **Low positive ER with no internal control cells:** “No internal controls are present, but external controls are appropriately positive. If needed, testing another specimen that contains internal controls may be warranted for confirmation of ER status.”
- **Negative ER with no internal control cells:** “No internal controls are present, but external controls are appropriately positive. If needed, testing another specimen that contains internal controls may be warranted for confirmation of ER status.”
- **Negative and the pathologist is not satisfied with optimum fixation and processing conditions and the test cannot be repeated in another sample:** “False negative test results cannot be excluded due to \_\_\_\_\_ (reason)”



## Reporting guidelines

### ASCO/CAP Guideline Update 2020 for ER and PR testing

#### Estrogen receptor

Positive	>10% of cells demonstrate nuclear positivity of any intensity
Low positive	1-10% of cells with nuclear positivity of any intensity
Negative	less than 1% of cells with nuclear positivity of any intensity

#### Progesterone receptor

Positive	>1% of cells demonstrate nuclear positivity of any intensity
Negative	less than 1%

### Allred Scoring System for ER and PR

Score for Proportion Staining (PS) + Score for Staining Intensity (IS)

0 = No nuclear staining	0 = No staining
1 = < 1% nuclei staining	1 = Weak staining
2 = 1 – 10% nuclei staining *	2 = Moderate staining
3 = 11 -33% nuclei staining	3 = Strong staining
4 = 34 -66% nuclei staining	
5 = 67 -100% nuclei staining	

**TOTAL SCORE = PS + IS**

### ASCO/CAP Guideline Update 2018 for HER2 testing

Result category	Score to report	Staining pattern
Negative	0	No staining is seen or incomplete membrane staining that is faintly perceptible and in $\leq 10\%$ of cells
Negative	1+	Incomplete membrane staining that is faintly perceptible and in $>10\%$ of cells
Equivocal	2+	Weak to moderate complete membrane staining in $>10\%$ of cells
Positive	3+	Circumferential membrane staining that is complete, intense and in $>10\%$ of cells

## References

1. Allison KH, M. Hammond MEH, Dowsett M et al. Estrogen and Progesterone Receptor Testing in Breast Cancer: ASCO/CAP Guideline Update. J Clin Oncol 2020; 38:1346-1366. DOI: 10.1200/JCO.19.02309. PMID: 31928404
2. Ellis IO, Carder P, Hales S et al. Pathology reporting of breast disease in surgical excision specimens incorporating the dataset for histological reporting of breast cancer. Royal College of Pathologists, 2016. Available at : [https://www.rcpath.org/uploads/assets/7763be1c-d330-40e8-95d08f955752792a/G148\\_BreastDataset-hires-Jun16.pdf](https://www.rcpath.org/uploads/assets/7763be1c-d330-40e8-95d08f955752792a/G148_BreastDataset-hires-Jun16.pdf)

3. Wolff AC, Hammond MEH, Allison KH et al. Human Epidermal Growth Factor Receptor 2 Testing in Breast Cancer American Society of Clinical Oncology/College of American Pathologists Clinical Practice Guideline Focused Update. Arch Pathol Lab Med 2018;142: 1364-1382. DOI: 10.5858/arpa.2018-0902-SA. PMID: 29846104

